

## INVITED REVIEW

# A meta-analytic investigation of grey matter differences in anorexia nervosa and autism spectrum disorder

Michelle Sader<sup>1</sup> | Justin H. G. Williams<sup>1</sup> | Gordon D. Waiter<sup>2</sup>

<sup>1</sup>Translational Neuroscience, Institute of Medical Sciences, University of Aberdeen, Aberdeen, UK

<sup>2</sup>Biomedical Imaging Centre, Institute of Medical Sciences, University of Aberdeen, Aberdeen, UK

## Correspondence

Michelle Sader, Translational Neuroscience, Institute of Medical Sciences, University of Aberdeen, Aberdeen, UK.

Email: [m.sader.19@abdn.ac.uk](mailto:m.sader.19@abdn.ac.uk)

## Abstract

Recent research reports Anorexia Nervosa (AN) to be highly dependent upon neurobiological function. Some behaviours, particularly concerning food selectivity are found in populations with both Autism Spectrum Disorder (ASD) and AN, and there is a proportionally elevated number of anorexic patients exhibiting symptoms of ASD. We performed a systematic review of structural MRI literature with the aim of identifying common structural neural correlates common to both AN and ASD. Across 46 ASD publications, a meta-analysis of volumetric differences between ASD and healthy controls revealed no consistently affected brain regions. Meta-analysis of 23 AN publications revealed increased volume within the orbitofrontal cortex and medial temporal lobe, and adult-only AN literature revealed differences within the genu of the anterior cingulate cortex. The changes are consistent with alterations in flexible reward-related learning and episodic memory reported in neuropsychological studies. There was no structural overlap between ASD and AN. Findings suggest no consistent neuroanatomical abnormality associated with ASD, and evidence is lacking to suggest that reported behavioural similarities between those with AN and ASD are due to neuroanatomical structural similarities.

## KEYWORDS

anorexia nervosa, autism spectrum disorder, emotion awareness, meta-analysis, VBM

## Highlights

- Findings related to neuroanatomical structure in AN/ASD demonstrate overlap and require revisiting.

**Abbreviations:** ACC, anterior cingulate cortex; ADHD, attention deficit hyperactivity disorder; ALE, activation likelihood estimation; AN, anorexia nervosa; AQ, autism quotient; ASD, autism spectrum disorder; EQ, emotional quotient; FWE, family-wise error; GWAS, genome-wide association study; HC, healthy controls; LPFC, lateral prefrontal cortex; MFG, medial frontal gyrus; MNI, montreal neurological institute; MRI, magnetic resonance imaging; MTG, medial temporal gyrus; MTL, medial temporal lobe; OFC, orbitofrontal cortex; PDD, pervasive developmental disorder; PET, positron emission tomography; RAN, recovered anorexia nervosa; STS, superior temporal sulcus; VBM, voxel-based morphometry; WOS, web of science; WCST, wisconsin card sorting test.

This is an open access article under the terms of the Creative Commons Attribution-NonCommercial-NoDerivs License, which permits use and distribution in any medium, provided the original work is properly cited, the use is non-commercial and no modifications or adaptations are made.

© 2022 The Authors. European Eating Disorders Review published by Eating Disorders Association and John Wiley & Sons Ltd.

- Meta-analytic findings show structural increase/decrease versus healthy controls (LPFC/MTL/OFC) in AN, but no clusters found in ASD.
- The neuroanatomy associated with ASD is inconsistent, but findings in AN reflect condition-related impairment in executive function and socio-cognitive behaviours.

## 1 | INTRODUCTION

### 1.1 | An overview of anorexia nervosa and autism spectrum disorder

Anorexia nervosa (AN) is a severe and multifactorial eating disorder characterised by a pathological fear of putting on weight and a distorted body-image. This psychiatric condition results in extremely low body weight in the context of individual age, sex, and overall development. AN affects 8 in 100,000 people, and has the highest mortality rate of any psychiatric illness at 20% (Australian, 2005; Hoek, 2006). In tandem, ASD is a neurodevelopmental condition predominantly characterised by a wide range of pathological social and behavioural impairments. Social deficits reflect difficulty expressing reciprocal verbal and non-verbal behaviour, but patients may also show rigidity in behaviour and hypersensitivity to external stimuli (American Psychiatric Association, 2000). Significant financial (Lavelle et al., 2014) and emotional (Cakir et al., 2020) burdens, as well as increased reports of the condition have sparked global concern (Elsabbagh et al., 2012).

A growing body of work reports commonalities in the cognitive profiles and reported behavioural symptomatology between those with AN and ASD (Huke et al., 2013). Baron-Cohen (2013) discusses the existence of multiple factors connecting anorexic and autistic traits, such as impairment in empathy as well as food selectivity and difficulty eating in social settings (Baron-Cohen et al., 2013). A significant commonality expressed in both conditions relates to behavioural and attitude-based rigidity with a particular focus on food or weight in AN (Karlsson et al., 2013). A meta-analysis by Westwood et al. (2016) assessed cognitive flexibility in those with AN and ASD via the Wisconsin Card Sorting Test (WCST) (Heaton et al., 1993; Westwood et al., 2016). While there were no reports concerning effect of diagnosis on performance, ASD and AN groups made significantly higher perseverative errors. Moreover, both clinical groups share behavioural parallels related to difficulty in empathising or relating to others. Individuals with AN may show impaired empathy by employing most of their attentional resources internally and engaging in social comparison behaviour (Pollatos et al., 2016;

Westwood & Tchanturia, 2017). Impairment in executive function, central coherence and empathy has also been widely noted in those with autism (Baron-Cohen et al., 2001; Lombardo et al., 2007; Mul et al., 2018; Oldershaw et al., 2011; Warrier et al., 2018; Wheelwright et al., 2006). A genome-wide association (GWAS) study involving 46,861 participants evaluated the relationship between Emotional Quotient (EQ) performance and risk for neuropsychological conditions such as AN, ASD and schizophrenia. Significant negative correlations were found between EQ performance and ASD, as well as a positive correlation between EQ performance and genetic risk for anorexia nervosa (Warrier et al., 2018).

### 1.2 | Neuroimaging overlap

Beyond cognitive measurements, structural and functional imaging suggest that AN and ASD could share condition-related brain regions. A variety of previous research has reported aberrant functionality in both AN and ASD within social and appetitive centres such as the amygdala, cerebellum, insula, cingulate cortex, fusiform gyrus and superior temporal gyrus (Corbett et al., 2009; Joos et al., 2011; Liu et al., 2019; Philip et al., 2012; Zhu et al., 2012). The anterior cingulate cortex (ACC), insula and cerebellum, which are associated with emotional learning, have been reported to be discrepant in both anatomical size and structural connectivity when compared to controls (Ebisch et al., 2011; Kim et al., 2012; Silani et al., 2008; Titova et al., 2013; Zhang et al., 2018). The insula, hippocampus and cerebellum are three key regions of the brain reported to be structurally altered in both conditions (Gaudio et al., 2018; Gröne et al., 2015; Kim et al., 2012; Lee et al., 2014; Young et al., 2020; Zimmermann et al., 2019).

Abnormal neuroanatomical structure and function reported in AN and ASD is consistent with a growing body of work investigating emotional and cognitive disorder aspects, such as food selectivity, behavioural and attitude-based rigidity as well as impaired Theory of Mind (Burkert et al., 2015; Mul et al., 2018; Westwood et al., 2016). For example, increased activity of ACC has been noted to correlate with unpleasantness and pain processing, and has been associated with psychosocial

behaviours seen in AN, such as impaired emotional awareness and reasoning as well as increased alexithymia scores (Horndasch et al., 2018; Seitz et al., 2018). Increased volume of the orbitofrontal cortex (OFC) has been associated with food avoidance in AN (Frank et al., 2013). Other studies report reduced attention to facial stimuli and decreased understanding of other's emotions in AN (Kappou et al., 2021; Tottenham & Galván, 2016).

Voxel-based morphometry (VBM) is a widely utilised neuroimaging technique that investigates focal differences in neuroanatomy through segmentation, normalisation and smoothing of tissues into grey matter, white matter, and cerebrospinal fluid (Mechelli et al., 2005). VBM is particularly amenable to meta-analytic reviews as the method corrects for individual differences in structural anatomy (Ashburner & Friston, 2001), and may be utilised across groups of individuals.

Two previous meta-analyses have evaluated neuroanatomical structure in AN using VBM (Titova et al., 2013; Zhang et al., 2018). These studies both show findings of decreased volume within the cingulate cortex, hypothalamus and frontal/parietal lobes, but have not considered some more recent VBM findings (Brooks et al., 2011; Frank et al., 2013; Leppanen et al., 2019). In ASD, multiple VBM meta-analyses have examined condition-related neurocorrelates, reporting widespread structural alteration in white and grey matter volume, including the frontal/parietal lobes, medial temporal lobe, lateral occipital lobe, bilateral cerebellum, middle temporal gyrus, angular gyrus, fusiform gyrus, insula, right ACC, posterior cingulate cortex, caudate, amygdala and praecuneus (Cauda et al., 2011; DeRamus & Kana, 2015; Duerden et al., 2012; Liu et al., 2017; Nickl-Jockschat et al., 2012; Radua et al., 2011). However, individual studies examining the neuroanatomy associated with ASD often contain small sample sizes of less than 20 per cohort (Boddaert et al., 2004; Bonilha et al., 2008; Brieber et al., 2007; Craig et al., 2007; David et al., 2014; Li et al., 2019; Lim et al., 2015; Mueller et al., 2013; Richter et al., 2015; Waiter et al., 2005; Wilson et al., 2009). Additionally, no recent meta-analytic work has incorporated research from 2017 onwards. Despite previous meta-analytic VBM research in AN and ASD respectively, there are additionally no structural studies investigating overlap in brain structure, and existing review literature focuses on self-reported questionnaire measurements rather than MRI modalities (Kerr-Gaffney et al., 2019; Westwood et al., 2016). One VBM study of note conducted by Björnsdotter et al. (2018) (Björnsdotter et al., 2018) evaluated correlations between neuroanatomical structure and scores on the Autism Quotient (AQ) questionnaire in those with AN. Compared with

controls, those with AN exhibited decreased volume in the bilateral superior temporal sulcus (STS), with the left STS negatively correlating with AQ scores (Björnsdotter et al., 2018). However, this work consists of the limitation that use of the AQ questionnaire in a non-ASD population only serves as a behavioural marker, and cannot be considered a diagnostic factor of AN. In summary, AN/ASD-related neuroimaging research in the past decade has grown extensively and implicated possible regions of overlap, but requires further investigation.

We collated AN and ASD VBM literature utilising large-cohort MRI data to quantify, identify and elaborate upon regions of the brain associated with AN and ASD. While cross-sectional studies have limited capacity to understand the causal or longitudinal nature of neuroanatomical structure in AN or ASD, separately evaluating distinct age subgroups compared with the combined dataset will provide information regarding what specific regions of the brain are impacted within distinct age ranges, and whether an existing overlap in affected structure will change according to age.

## 2 | METHODOLOGY

### 2.1 | Selection of literature

Literature was selected using SCOPUS, PubMed, and Web of Science (WOS). From the used key terms, PubMed revealed 604 publications regarding states of hunger and anorexia (*search criteria*: [{Anorexia OR Anorex\* OR Anorexia nervosa OR AN OR Eating Disorder} AND {VBM OR voxel based morphometry AND structural magnetic resonance imaging OR sMRI}]). SCOPUS identified 3139 publications reflecting AN research. Lastly, WOS identified 2498 papers regarding AN or states of undereating ( $n_{\text{total}} = 6241$ ). For our ASD literature selection, PubMed revealed 1503 publications relating to ASD (*search criteria*: [{ASD OR Autis\* OR Asperger\* OR PDD OR Pervasive Developmental Disorder} AND {VBM AND voxel based morphometry AND structural magnetic resonance imaging OR sMRI}]). SCOPUS identified 2507 documents under the utilised search criteria and Web of Science identified 45 publications ( $n_{\text{total}} = 4055$ ) Initial inclusion criteria involved the presence of key phrases utilised in search. Exclusion criteria were as follows: (1) Publications older than 20 years, with 2000 as the cut-off range for literature selection; (2) Animal studies, (3) Publications lacking case-controls; (4) Meta-analyses; (5) No VBM analysis, or results not reported in Talairach or MNI coordinates. Within the AN literature selection, individual studies fitting search criteria were additionally collected from

identified meta-analyses ( $n = 4$ ). In sum, 46 ASD and 23 AN papers included coordinates and were selected for final analysis with 5236 total subjects ( $n_{\text{ASD}} = 2062$  vs.  $n_{\text{HC}} = 2044$ ;  $n_{\text{AN}} = 536$  &  $n_{\text{RAN}} = 37$  vs.  $n_{\text{HC}} = 557$ ) (Table 1). Seven hundred and eighty coordinates were collected from selected publications (Figure 1; Supplementary Table 1).

## 2.2 | Voxel-based morphometry and activation likelihood estimate analysis

Coordinates were obtained from the AN and ASD literature searches in Montreal Neurological Institute (MNI) and Talairach space. Coordinates were respectively incorporated into GingerALE, an Activation Likelihood Estimate (ALE) meta-analysis software (Eickhoff et al., 2009). GingerALE converted coordinates obtained in Talairach Spaces to MNI spaces using the *icbm2tal* transform.  $P$  thresholds for individual analyses were corrected for family-wise error (FWE) and set to  $p < 0.05$ . As the GingerALE software calculates studies reporting increase and decrease clusters separately, positive and negative volume differences in each clinical group were separately analysed and subsequently pooled together. Once whole-brain data for clinical groups independent of age was combined, further analyses were conducted to analyse neuroanatomical structure in the adult (21+ years old) literature and identify if findings are significantly different than those from child (0–20 years old) studies. Data was then pooled to observe respective increases and decreases dependent on age. There was insufficient literature to compare child-only studies in AN with our combined dataset.

Once age-dependent clusters were identified by the GingerALE software, results were compared between AN and ASD for a final conjunction analysis to investigating potential overlap in volume abnormalities within age-dependent subgroups. FWE-corrected clusters produced by GingerALE were visualised on *Mango* (Lancaster & Martinez, 2011). Using an MNI template file, the output FWE-corrected clusters generated from GingerALE are inserted as an overlay to visualise regions to identify any overlap in affected regions. In order to prevent conflation of AN, ASD and pooled sample data, any conjunction analyses on reported increase/decrease results were conducted separately. Executing separate analyses for increase and decrease data allows a given result value to retain its significance amongst scientific literature, as well as prevents duplication of sample sizes. Subject data was uncorrected under a threshold of  $p < 0.05$ .

## 3 | RESULTS

In summary, 70 papers (Amianto et al., 2013; Bär et al., 2015; Björnsdotter et al., 2018; Boddaert et al., 2004; Boghi et al., 2011; Bonilha et al., 2008; Brieber et al., 2007; Brooks et al., 2011; Cai et al., 2018; Castro-Fornieles et al., 2009; Craig et al., 2007; D'Agata et al., 2015; David et al., 2014; Duerden et al., 2012; Floris et al., 2016; Fonville et al., 2014; Frank et al., 2013; Friederich et al., 2012; Fujisawa et al., 2015; Gaudio et al., 2011; Hanaie et al., 2016; Joos et al., 2011; Kohmura et al., 2017; Kojima et al., 2019; Lázaro et al., 2013; Leppanen et al., 2019; Li et al., 2019; Lim et al., 2015; Lin et al., 2015; Martin Monzon et al., 2017; Mueller et al., 2013; Ni et al., 2018; Nickel et al., 2018; Parellada et al., 2017; Retico et al., 2016; Richter et al., 2015; Sato et al., 2017; Suchan et al., 2010; Uddin et al., 2011; VanOpstal et al., 2015; Waiter et al., 2005; Wang et al., 2017; Wilson et al., 2009; Yang et al., 2016) included coordinates and were selected for final analysis with 5484 total subjects ( $n_{\text{AN}} = 562$  &  $n_{\text{Recovered AN [RAN]}} = 37$  vs.  $n_{\text{HC}} = 584$ ;  $n_{\text{ASD}} = 2164$  vs.  $n_{\text{HC}} = 2137$ ) (Table 1). Seven hundred and eighty six coordinates were collected from the selected publications (Figure 1). This study also included work related to the ABIDE II dataset, which consists of large-scale health and imaging cohort data of those with ASD relative to controls. To prevent conflation of ABIDE II data, the publication with the largest ABIDE II sample size to date was included for analysis (Osipowicz et al., 2015). Collected literature in AN was female-predominant, with only two publications recruiting male subjects (Bär et al., 2015; Boghi et al., 2011). Meanwhile, literature in ASD was strongly-male predominant, with two publications recruiting female-only subjects (Calderoni et al., 2012; Craig et al., 2007). Mean participant age was  $21.0 \pm 4.22$  for AN subjects ( $\text{RAN} = 26.05 \pm 6$ ) and  $21.5 \pm 3.18$  for HCs, and the mean age in ASD publications was  $15.6 \pm 9.4$  for ASD and  $15.6 \pm 9.1$  for HCs.

### 3.1 | Volumetric increase and decrease in autism spectrum disorder

Despite a multitude of previous brain regions being reported in VBM literature (Figure 2), no significant clusters indicating positive or negative volume differences were found when testing all ASD data at  $p < 0.001$  or under FWE correction at  $p < 0.05$ , both dependent and independent of age.

TABLE 1 Demographics for the publications pertaining to aberrant brain volume in both AN and ASD data

[AN]	No. Subjects			Age, y (mean ± SD)				BMI (kg/m <sup>2</sup> )				Correction			
	nAN	nHC	nRAN	nTotal	M:F ratio	nAN	nHC	nRAN	A <sup>a</sup>	nAN	nHC	nRAN	Doi (y)	Corr. Type <sup>b</sup>	Thresh.
Nickel, 2018	34	41	24	99	0:99	23.8 ± 4.3	23.6 ± 3.8	27.1 ± 7.1	1	16.1 ± 1.4	22.3 ± 2.4	20.6 ± 1.3	AN: 6.6 ± 3.7; RAN: 7.2 ± 4.7	FWE	p < 0.05
Björnsdotter, 2018	25	25	0	50	0:50	20.3 ± 2.2	21.3 ± 2.1	N/A	1	16.3 ± 0.9	21.1 ± 2.3	N/A	4.14 ± 3.54	FWE	p < 0.05
Martin Monzon, 2017	26	20	0	46	0:46	16.5 ± 0.3	17.3 ± 0.3	N/A	0	16.7 ± 0.2	22.60 ± 0.90	N/A	<3	FDR	p < 0.05
Kohmura, 2017	23	29	0	52	0:52	28.5 ± 6.7	28.2 ± 7.0	N/A	1	13.2 ± 1.5	21.5 ± 3.3	N/A	10.5 ± 6.2	FWE	p < 0.05
Fuglset, 2016	23	28	0	51	0:51	17.4 ± 2.2	17.6 ± 2.2	N/A	0	17.4 ± 2.0	21.8 ± 2.8	N/A	N/A	CPW	p < 0.05
Seitz, 2015	56	50	0	106	0:106	15.5 ± 1.7	15.8 ± 1.7	N/A	0	15.1 ± 1.4	21.4 ± 3.3	N/A	0.95 ± 0.69	BMC	p < 0.01
Fujisawa, 2015	20	14	0	34	0:34	14.2 ± 1.8	14.9 ± 1.6	N/A	0	14.4 ± 2	N/A	N/A	1.96 ± 1.1	FWE	p < 0.05
Van Opstal, 2015	10	11	0	21	0:21	22.1 ± 3.3	20.8 ± 0.5	N/A	1	15.6 ± 1	20.3 ± 1.5	N/A	3.54 ± 2.30	N/A	p < 0.05
D'Agata, 2015	21	17	0	38	0:38	21 ± 5	23 ± 4	N/A	1	16.1 ± 0.9	21.5 ± 2.3	N/A	<2	N/A	p < 0.05
Bär, 2015	26	26	0	52	3:23	22.9 ± 5	24 ± 1.9	N/A	1	17 ± 1.5	21.7 ± 1.5	N/A	1.86 ± 1.23	FWE	p < 0.05
Frank, 2013	19	22	0	41	0:41	15.4 ± 1.4	14.8 ± 1.8	N/A	0	16.2 ± 1.1	21.3 ± 1.9	N/A	N/A	FWE	p < 0.05
Lázaro, 2013	35	17	0	52	0:52	16.3 ± 1.3	16.7 ± 1.5	N/A	0	19.3 ± 1.1	N/A	N/A	0.62 ± 0.43	FWE	p < 0.05
Amianto, 2013	17	14	0	31	0:31	20 ± 4	24 ± 3	N/A	1	16 ± 1	21 ± 2	N/A	1.08 ± 0.67	0	p < 0.005
Brooks, 2011	14	21	0	35	0:35	26 ± 1.9	26 ± 2.1	N/A	1	15.6 ± 0.4	21.4 ± 0.5	N/A	9.2 ± 1.9	FDR	p < 0.05
Friederich, 2012	12	14	13	39	0:39	24.3 ± 6.2	25.6 ± 3.7	25.0 ± 4.8	1	15.9 ± 1.6	21.1 ± 1.5	19.5 ± 1.4	AN: 6.3 ± 4.4; RAN: 5.7 ± 3.6	1	p < 0.05
Boghi, 2011	21	27	0	48	0:48	29 ± 10	30.8 ± 8.7	N/A	1	15.5 ± 1.8	21.9 ± 1.5	N/A	11.3 ± 12.1	FDR	p < 0.05
Joos, 2011	12	18	0	30	0:30	25.0 ± 4.8	26.9 ± 5.7	N/A	1	16 ± 1.2	21.2 ± 2.0	N/A	4.7 ± 3.6	1	p < 0.05
Castro-Fornieles, 2009	12	9	0	21	AN: 1:11; HC: 1:9	14.5 ± 1.5	14.6 ± 3.2	N/A	0	14.8 ± 2.0	N/A	N/A	0.69 ± 0.26	FWE	p < 0.05
Leppanen, 2019	46	54	0	100	0:100	27.51 ± 9.2	26.4 ± 4.5	N/A	1	15.7 ± 1.41	21.5 ± 2	N/A	11.39 ± 9.2	FDR	p < 0.001
Fonville, 2014	31	31	0	62	0:62	23 ± 10.0	25 ± 4.0	N/A	1	15.8 ± 1.4	21.8 ± 1.8	N/A	7 ± 10	FWE	p < 0.05
Suchan, 2010	15	15	0	30	0:30	26.8 ± 8.4	29.5 ± 8.2	N/A	1	16 ± 1.3	22 ± 2.1	N/A	5.5 ± 5.0	FDR	p < 0.05
Gaudio, 2011	16	16	0	32	0:32	15.2 ± 1.7	15.1 ± 1.5	N/A	0	14.2 ± 1.4	20.2 ± 1.6	N/A	0.44 ± 0.267	FWE	p < 0.05
Oliveo, 2018	22	38	0	60	0:60	14.9 ± 1.6	14.7 ± 1.3	N/A	0	19.3 ± 2.0	20.7 ± 2.3	N/A	0.66 ± 0.4	FWE	p < 0.05

TABLE 1 (Continued)

[ASD] First author	No. Subjects		Age, y (mean ± SD)		M:F ratio	nTotal	nHC	nASD	nHC	A <sup>a</sup>	BMI (kg/m <sup>2</sup> )	Correction		
	nASD	nHC	nASD	nHC								Corr. Type <sup>b</sup>	Thresh.	
Cai, 2018	38	27	65	ASD: 16:3; HC: 26:1		65	27	9.56 ± 3.43	8.33 ± 2.3	0	-	-	0	p < 0.001
Kojima, 2019	39	39	78	78:0		78	39	29.9 ± 6.8	31.5 ± 4.5	1	-	-	0	p < 0.05
Ni, 2018	85	61	146	146:0		146	61	13.0 ± 2.0	12.0 ± 2.2	0	-	-	FWE	p < 0.01
Wang, 2017	31	31	62	62:0		62	31	4.31 ± 1.12	4.83 ± 0.85	0	-	-	GRF	p < 0.05
Sato, 2017	36	36	72	25:11		72	36	27.0 ± 8.0	24.9 ± 5.5	1	-	-	FDR	p < 0.05
Parellada, 2017	30	26	56	ASD: 14:1; HC: 25:1		56	26	13.3 ± 1.99	13.1 ± 2.43	0	-	-	0	p < 0.05
Yang, 2016	60	41	101	101:0		101	41	8.35 ± 2.07	8.83 ± 2.30	0	-	-	0	p < 0.05
Hanaie, 2016	20	21	41	ASD: 19:1; HC: 20:1		41	21	9.5 ± 2.5	10.1 ± 2.3	0	-	-	0	p < 0.001
Retico, 2016	76	76	152	1:01		152	76	4.4 ± 1.4	4.4 ± 1.5	0	-	-	SVM	p < 0.05
Floris, 2016	67	69	136	136:0		136	69	26.19 ± 6.79	27.88 ± 5.99	1	-	-	FDR	p < 0.025
Lin, 2015	86	90	176	176:0		176	90	15.0 ± 4.6	15.7 ± 6.0	0	-	-	FWE	p < 0.05
Lim, 2015	19	33	52	52:0		52	33	14.9 ± 1.86	14.3 ± 2.52	0	-	-	FWE	p < 0.05
Radeloff, 2014	34	26	60	ASD: 31:3; HC: 11:2		60	26	19.06 ± 5.12	19.54 ± 3.46	1	-	-	0	p < 0.001
Xiao, 2014	50	28	78	ASD: 21:4; HC: 11:3		78	28	2.49 ± 0.46	2.35 ± 0.37	0	-	-	0	p < 0.001
Ecker, 2013	84	84	168	168:0		168	84	26 ± 7	28 ± 6	1	-	-	1	p < 0.05
Greimel, 2013	47	51	98	98:0		98	51	21.4 ± 10.1	18.3 ± 7.5	1	-	-	Bayesian	p < 0.05
Mengotti, 2011	20	22	42	ASD: 9:1; HC: 10:1		42	22	7 ± 2.75	7.68 ± 2.03	0	-	-	0	p < 0.001
Toal, 2010	26	33	59	ASD: 21:5; HC: 10:1		59	33	30 ± 8	32 ± 9	1	-	-	FWE	p < 0.05
Wilson, 2009	10	10	20	ASD: 4:1; HC: 7:3		20	10	30.10 ± 9.18	29.40 ± 7.91	1	-	-	FDR	p < 0.05
Hyde, 2010	15	15	30	30:0		30	15	22.7 ± 6.4	19.2 ± 5.0	1	-	-	FDR	p < 0.05
Brieber, 2007	15	15	30	30:0		30	15	14.2 ± 1.9	13.3 ± 1.8	0	-	-	0	p < 0.001
Rojas, 2006	24	23	47	47:0		47	23	20.79 ± 10.58	21.41 ± 10.91	1	-	-	SVC	p < 0.05
Boddaert, 2004	21	12	33	ASD: 16:5; HC: 3:1		33	12	9.3 ± 2.2	10.8 ± 2.7	0	-	-	SVC	p < 0.05
Mueller, 2013	12	12	24	ASD: 3:1; HC: 4:1		24	12	35.5 ± 11.4	33.3 ± 9.0	1	-	-	FWE	2.3 < z < 10
McAlonan, 2009	36	55	91	ASD: 30:6; HC: 47:8		91	55	11.55 ± 9.58	10.67 ± 0.891	0	-	-	FWE	<1 fpc
Duerden, 2012	33	30	63	ASD: 29:4; HC: 13:2		63	30	10.7 ± 2.5	10.7 ± 2.6	0	-	-	RFT	p < 0.05

(Continues)

TABLE 1 (Continued)

[ASD] First author	No. Subjects			Age, y (mean ± SD)			Correction				
	nASD	nHC	nTotal	M:F ratio	nASD	nHC	A <sup>a</sup>	BMI (kg/m <sup>2</sup> )	Corr. Type <sup>b</sup>	Thresh.	
Bonilha, 2008	12	16	28	28:0	12.4 ± 4.0	13.2 ± 5.0	0	-	-	FDR	p < 0.05
Calderoni, 2012	38	38	76	0:76	4.42 ± 1.5	4.42 ± 1.6	0	-	-	FDR	p < 0.05
Cheng, 2011	25	25	50	50:0	13.7 ± 2.5	13.5 ± 2.1	0	-	-	FWE	p < 0.05
Foster, 2015	38	46	84	ASD: 38:0; HC: 21:25	12.4 ± 2.9	12.6 ± 3.0	0	-	-	0	p < 0.001
Kurth, 2011	52	52	104	19:7	11.2 ± 3.95	11.14 ± 3.58	0	-	-	FWE	p < 0.05
Riva, 2013	26	21	47	ASD: 23:3; HC: 13:8	5.83 ± 2.5	6.83 ± 2.08	0	-	-	FDR	p < 0.05
Waiter, 2005	15	16	31	31:0	15.2 ± 2.2	15.5 ± 1.6	0	-	-	FDR	p < 0.05
Craig, 2007	14	19	33	0:33	37.9 ± 11.4	35.0 ± 14.0	1	-	-	0	<1 fpc
Li, 2019	16	16	32	32:0	8.81 ± 3.10	10.75 ± 2.86	0	-	-	AMC	p < 0.001
Raznahan, 2013	66	29	95	95:0	3.8 ± 1.0	3.8 ± 1.1	0	-	-	BMC	p < 0.05
Osipowicz, 2015	531	571	1102	ASD: 430:101; HC: 468:103	17 ± 8	17 ± 8	1	-	-	FWE	p < 0.05
Waiter, 2004	16	16	32	32:0	15.2 ± 2.24	15.1 ± 1.6	0	-	-	0	p < 0.001
Kosaka, 2010	32	40	72	72:0	23.8 ± 4.2	22.5 ± 4.3	1	-	-	FDR	p < 0.05
Richter, 2015	18	18	36	8:1	9.7 ± 2.1	9.7 ± 1.9	0	-	-	FDR	p < 0.05
D'Mello, 2015	35	35	70	ASD: 6:1; HC: 21:14	10.4 ± 1.6	10.4 ± 1.5	0	-	-	0	p < 0.001
David, 2014	15	14	29	ASD: 7:8; HC 7:7	33.2 ± 7.4	32.9 ± 7.6	1	-	-	0	p < 0.001
Zielinski, 2012	49	49	98	49:0	13.27 ± 5.1	13.67 ± 5.53	0	-	-	FWE	p < 0.01
Pereira, 2018	22	29	51	ASD: 9:2; HC: 19:10	18.48 ± 2.8	17.45 ± 3.29	0	-	-	0	p < 0.001
Scheel, 2011	28	28	56	9:5	33.1 ± 9.7	33.0 ± 9.2	1	-	-	CWP	p < 0.05
Itahashi, 2015	46	46	92	92:0	30.21 ± 7.5	30.54 ± 6.39	1	-	-	FDR	p < 0.05

Abbreviations: AMC, Alphasim Multiple Comparisons; BMC, Bonferroni Multiple Comparisons; CWP, Clustewise Corrected P; FDR, False Discovery Rate; FWE, Family Wise Error; GRF, Gaussian Random Field; RFT, Random Field Theory; SVM, Support Vector Machine; SVC, Small Volume Correction.

<sup>a</sup>Adult Sample Present; 1=yes; 0=no.

<sup>b</sup>Correction Type; 1-Posthoc correction used, unknown test; 0-No posthoc correction used.

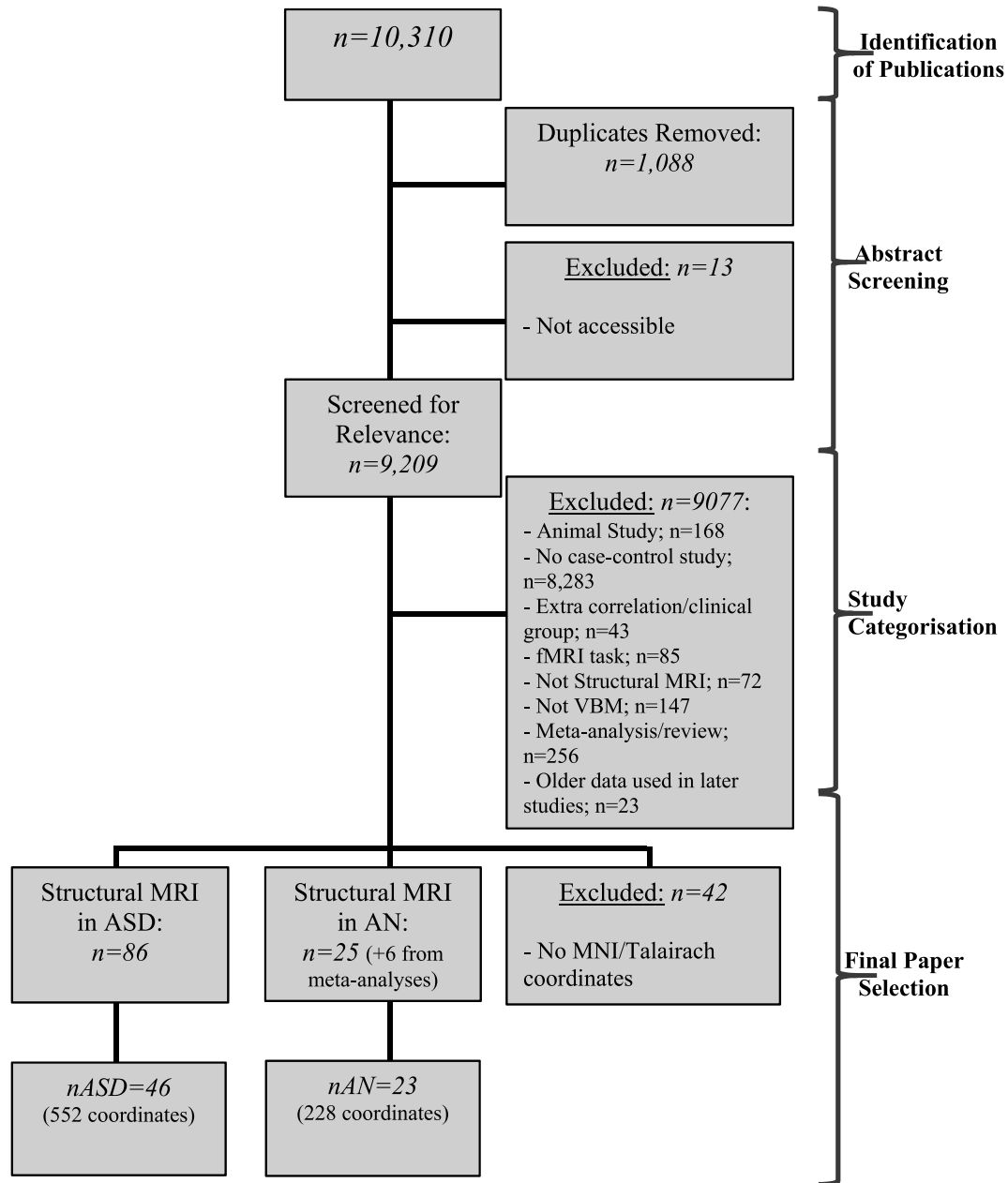


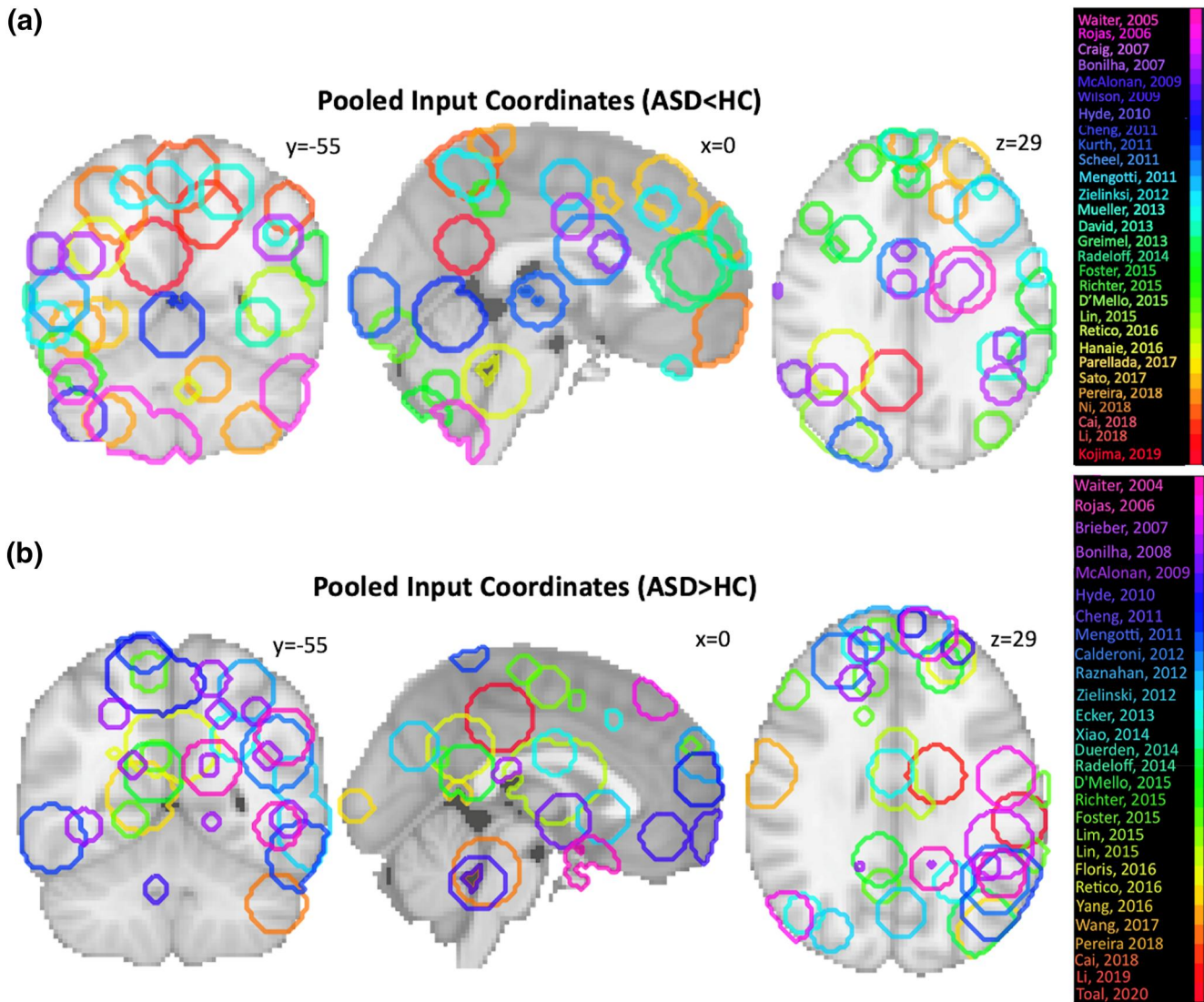
FIGURE 1 Flowchart depicting the identification, screening, and acquisition of data

### 3.2 | Volumetric increase and decrease in anorexia nervosa

Combining all coordinates from AN papers published within the past 20 years revealed significant differences in grey matter volume within a number of regions. Results of the GingerALE analysis identified three clusters of increased volume primarily located within the left and right medial temporal lobes. The largest cluster (28.72 cm<sup>3</sup>) with a centre at  $x = 29, y = -21, z = -22$  was largely located within the right parahippocampal gyrus. A second cluster (16.12 cm<sup>3</sup>) was located within the left uncus and amygdala with a centre at  $x = -32, y = -7,$

$z = -41$ . A third cluster was (8.58 cm<sup>3</sup>) was located on the left OFC and surrounding medial frontal gyrus (MFG) with a centre at  $x = -7, y = 38, z = -25$  (Table 2). While areas of increased volume were predominantly surface-based, they also included subcortical structures such as the amygdala and hippocampus (Figure 3.1). Results additionally identified a singular cluster reflecting volume reduction in AN subjects compared with a typical population primarily located within the right cingulate gyrus (7.29 cm<sup>3</sup>) with a centre at  $x = 10, y = -28, z = 44$  (Table 2). The praecuneus, lateral prefrontal cortex and paracentral lobule additionally demonstrated reductions in volume (Figure 3.2).





**FIGURE 2** Input coordinates delineated via Nilearn (Python) demonstrate the extensive diversity of implicated structural decrease (a) and increase (b) across case-control ASD literature. As not all publications are visible from one brain slice, MNI coordinates represent slices of the brain with the majority of visible clusters from available literature [Colour figure can be viewed at [wileyonlinelibrary.com](https://onlinelibrary.wiley.com)]

Repeating analysis of AN data after removal of child publications altered the findings in some respects, and identified significant additional differences when compared with all collated data (Supplementary Figure 1). As with the all-data analysis, analysis revealed three large clusters indicating increase in volume. The largest cluster ( $14 \text{ cm}^3$ ) with a centre at  $x = 12, y = -38, z = 52$  was predominantly located within the right paracentral lobule. The second cluster ( $12.18 \text{ cm}^3$ ) was located within the left anterior cingulate cortex (L ACC). The third cluster was found within the right lateral prefrontal cortex and was centred at  $x = 38, y = 52, z = 20$ . Similar to results when all data was included, removal of child data additionally revealed a large cluster of decreased volume within the right cingulate gyrus, with slightly increased volume ( $13.15\text{--}17.77 \text{ cm}^3$ )

(Supplementary Table 2). In contrast to analysing all AN data, the adult-only clusters indicated that peaks of significance were more focussed within the ACC as opposed to the OFC observed in the entire dataset.

## 4 | DISCUSSION

This systematic review and meta-analysis presents the first analysis of VBM literature comparing AN and ASD with 70 publications contributing to the study. Inspecting the diverse range of implicated regions from publications identified in this review (Figure 2), we found no significant clusters indicating regions with common or consistent volumetric increase or decrease when comparing ASD relative to HCs. Separating data by age also showed

**TABLE 2** Decreased GMV in AN participants relative to healthy controls (AN < HC) including all AN studies ( $n = 23$ ). Data is presented in order of significance values ( $p$  &  $Z$ ), with bolded coordinate sets comprising of cluster centres

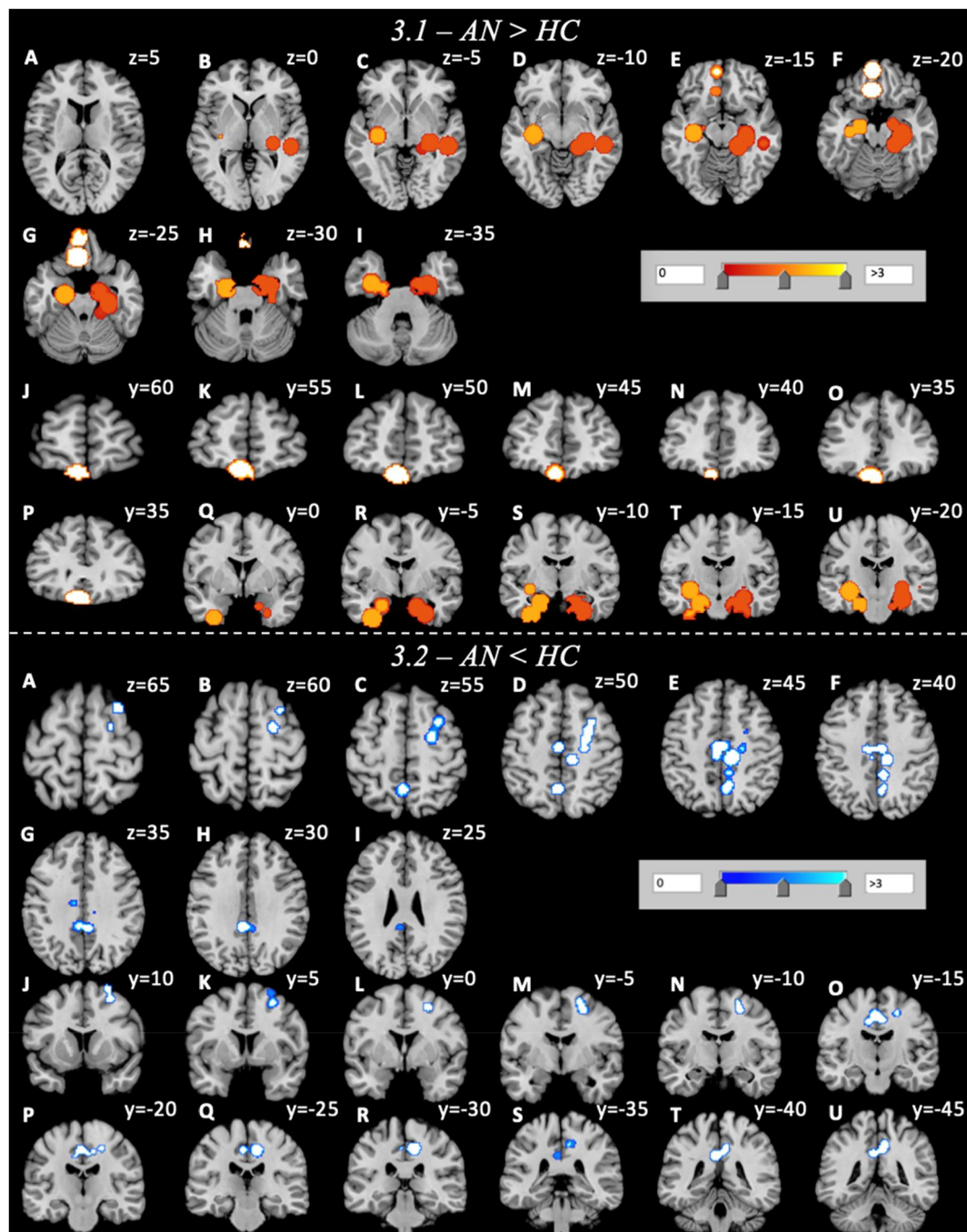
[All data] AN > HC	Region	BA	MNI coordinates			Volume (mm <sup>3</sup> )	ALE score	P	Z
			$x$	$y$	$z$				
<b>C1</b>	<b>R Parahippocampal Gyrus</b>	<b>35</b>	<b>28.8</b>	<b>-21.2</b>	<b>-21.5</b>	<b>28,720</b>	<b>0.0078</b>	<b>9.12E-04</b>	<b>3.12</b>
C1	R Parahippocampal Gyrus	28	29	-24.3	-16		0.0051	3.50E-03	2.7
<b>C2</b>	<b>L Uncus</b>	<b>36</b>	<b>-32</b>	<b>-7</b>	<b>-41</b>	<b>16,123</b>	<b>0.009</b>	<b>2.22E-04</b>	<b>3.51</b>
C2	L Parahippocampal Gyrus	N/A	-27	-16	-19		5.03E-04	2.94E-02	1.89
<b>C3</b>	<b>L Orbitofrontal Cortex (MFG)</b>	<b>11</b>	<b>-6.7</b>	<b>37.7</b>	<b>-25.3</b>	<b>8584</b>	<b>9.54E-04</b>	<b>2.10E-02</b>	<b>2.03</b>
<b>AN &lt; HC</b>									
<b>C1</b>	<b>R Cingulate Gyrus</b>	<b>31</b>	<b>10</b>	<b>-28</b>	<b>44</b>	<b>13,152</b>	<b>0.024</b>	<b>5.25E-07</b>	<b>4.89</b>
C1	L Cingulate Gyrus	31	-4	-40	32		0.016	7.98E-05	3.78
C1	L Praecuneus	7	-4	-56	52		0.015	1.39E-04	3.63
C1	L Paracentral Lobule	31	-2	-16	46		1.50E-02	1.46E-04	3.62
C1	R Praecuneus	7	6	-58	44		1.30E-02	5.38E-04	3.27
C1	R Cingulate Gyrus	31	8	-44	40		0.012	8.83E-04	3.13
C1	R LPFC (Middle Frontal Gyrus)	6	24	-6	52		0.012	8.97E-04	3.12
C1	R LPFC (Middle Frontal Gyrus)	6	26	-2	50		1.90E-02	1.01E-03	3.09
C1	R LPFC (Middle Frontal Gyrus)	6	22	-6	58		1.10E-02	1.64E-03	2.94
C1	R Sub-Gyral	6	30	8	54		0.011	2.02E-03	2.87
C1	L Cingulate Gyrus	31	-4	-26	44		0.01	2.97E-03	2.75
C1	L Cingulate Gyrus	24	-10	-16	38		1.00E-02	3.17E-03	2.73
C1	R LPFC (Middle Frontal Gyrus)	6	26	8	64		1.00E-02	3.91E-03	2.65
C1	R Cingulate Gyrus	31	22	-18	48		9.00E-03	4.55E-03	2.6

Abbreviations: BA, Brodmann Area; C, Cluster; L, left; LPFC, Lateral prefrontal cortex; MFG, Medial frontal gyrus; R, right.

no significant common volumetric differences in those with ASD relative to controls across the literature. In contrast, review of AN literature demonstrated marked effects in regions of the brain associated with executive function, memory consolidation, conflict monitoring and decision-making. Age-dependent analyses delineate further structural aberrance of the ACC when comparing adult and child cohorts.

Regarding our review of ASD VBM literature, a lack of condition-associated regions directly contradicts previously reported meta-analytic findings in ASD (Cauda et al., 2011; DeRamus & Kana, 2015; Duerden et al., 2012; Liu et al., 2017; Nickl-Jockschat et al., 2012; Radua et al., 2011). Previous reviews report disturbance within the cerebellum (Cauda et al., 2011), praecuneus (Liu et al., 2017), cingulate cortex (Cauda et al., 2011), fusiform gyrus (Cauda et al., 2011), fronto-temporal lobes (Cauda et al., 2011; DeRamus & Kana, 2015; Duerden et al., 2012; Liu et al., 2017; Nickl-Jockschat et al., 2012), parietal lobes (Cauda et al., 2011;

DeRamus & Kana, 2015), occipital lobes (DeRamus & Kana, 2015; Duerden et al., 2012; Liu et al., 2017; Radua et al., 2011) and the basal ganglia (Duerden et al., 2012; Nickl-Jockschat et al., 2012; Radua et al., 2011). However, it is pertinent to note the extreme diversity in associated brain regions and direction of effect. For instance, findings regarding the temporal lobe of the brain, implicated in the majority of previous VBM reviews, were discrepant in location and affected either the medial temporal lobe/gyrus (MTL/G) (Cauda et al., 2011; Duerden et al., 2012), inferior temporal gyrus (Liu et al., 2017) or temporal poles (DeRamus & Kana, 2015). Additionally, such findings are unable to unilaterally confirm whether the temporal lobe is structurally increased (Cauda et al., 2011; Liu et al., 2017; Nickl-Jockschat et al., 2012) or decreased (Cauda et al., 2011; DeRamus & Kana, 2015; Nickl-Jockschat et al., 2012) in those with ASD relative to controls. Regional discrepancies pertaining to location and effect can also be identified within the cerebellum



**FIGURE 3** Clusters of volume increase (3.1) and decrease (3.2) in AN participants relative to healthy controls. Volumetric increase in those with AN spans from  $z = 5$  to  $z = -35$ ,  $y = 50$  to  $y = 20/y = 0$  to  $y = -20$  and  $x = -30$  to  $x = 30$  in axial (A–I) and coronal (J–U) orientations. Volumetric decrease in those with AN spans from  $z = 65$  to  $z = 20$ ,  $y = 10$  to  $y = -45$  and  $x = -5$  to  $x = 25$  in axial (A–I) and coronal (J–U) orientations [Colour figure can be viewed at [wileyonlinelibrary.com](http://wileyonlinelibrary.com)]

(Cauda et al., 2011) and frontal brain regions (i.e., middle frontal gyrus, prefrontal cortex) (DeRamus & Kana, 2015; Duerden et al., 2012; Liu et al., 2017). Further, some reviews note that volumetric abnormalities, particularly structural reduction, are dependent on age (DeRamus & Kana, 2015; Duerden et al., 2012; Nickl-Jockschat et al., 2012), while other reviews either did not identify associations between age and regional

volume (Radua et al., 2011), or were assessing age-specific cohorts (Liu et al., 2017; Radua et al., 2011).

A lack of consistent condition-associated brain regions in this meta-analysis may also be explained by high level of heterogeneity and comorbidity that occurs in ASD. For example, estimates of the frequency of intellectual impairment are highly varied in ASD, ranging from 10% to 90% depending on sampling and diagnostic

definitions (Bougeard et al., 2021). Anxiety and ADHD are other commonly presented neurodevelopmental problems (Georgiades et al., 2013). Thus, neurodevelopmental impairment may commonly occur in ASD which is not directly related to the behavioural syndrome that characterises ASD. Structural neuroimaging studies are cross-sectional and only identify associations rather than causative links between differences and condition. It is therefore possible that differences reported in previous studies reflect associations with non-specific neural correlates, rather than specific neural correlates which characterise and may play a causal role in the aetiology of ASD. Altogether, the diverse array of implicated regions and contrasting findings regarding structural effect in previous ASD literature in tandem with characteristic heterogeneity of causes may explain the absence of consistent findings seen in this meta-analysis.

In contrast to the ASD analysis, a review of AN VBM literature provides an updated report demonstrating significantly altered neuroanatomy associated with the AN cohort compared to controls, and is the first quantitative analysis to report volumetric *increase* in AN (Titova et al., 2013; Zhang et al., 2018). Results from analysing 23 AN publications revealed common regions of increased volume in the parahippocampal gyrus, OFC and MTL/medial frontal gyrus (MFG). The OFC is tightly interconnected with the ACC which work together to modulate reward- and appetite-based learning (Price et al., 1991; Rolls, 2004). This brain region plays important roles in regulating food intake and contains the site where the reward/value of taste is processed (Price et al., 1991). The OFC also integrates aversive forms of taste, and is subject to reinforcement association to positive and negative stimuli (Rolls, 2004). OFC-related predictions based on individual reward value may play an important role in those with AN, as food may become associated with a prediction of weight gain and negative body image, both of which become strongly aversive stimuli in AN. Our findings regarding increased or unusual OFC volume in AN have not been identified by previous VBM meta-analyses (Titova et al., 2013; Zhang et al., 2018). However, a growing number of authors identify increased OFC volume and cortical thickness, and suggest that the OFC may contribute to traits of food avoidance in AN (Brooks et al., 2011; Cascino et al., 2020; Lavagnino et al., 2018).

Abnormal parahippocampal gyrus volume has been previously reported in AN (Bomba et al., 2014; Castellon et al., 2020; Huber et al., 2015) and serves important roles in episodic memory, including visual scene recognition, encoding, retrieval (Aguirre et al., 1998; Ward et al., 2014), autobiographical memory formation (Boccia

et al., 2019; Bomba et al., 2014; Huber et al., 2015; McCrory et al., 2017) and integration of social contexts (Akimoto et al., 2014; Rudolph et al., 2020). Findings reflect a model presented by (Riva, 2016) explaining how increased autobiographical memory for negative experiences in AN affects egocentric body memory and lead to distorted body image (Riva, 2016). The parahippocampal cortex is important the computation of third-person or allocentric memories, both autobiographical and episodic (Ekstrom et al., 2014).

Decreased volume in AN relative to HCs was observed in the bilateral cingulate gyrus, right lateral prefrontal cortex (LPFC)/middle frontal gyrus, cuneus and paracentral cortex. In AN, reduction of the LPFC may be involved in the cognitive and motor aspects of inhibitory control as a means to maintain dietary restriction.

Analysis upon removal of child studies revealed distinct regions of abnormal neuroanatomy when compared with the entire AN cohort. While clusters of reduced volume were relatively unaffected, states of increased volume greatly differed between adult-only AN data and the collected dataset. The right superior/MFG and ACC were the most affected, with the ACC cluster not appearing in our all-cohort analysis. This cluster also comprised of the most anteriorly-located subregion of the corpus callosum, known as the genu. Adult findings also demonstrated significantly increased volume of the paracentral lobule, as well as slightly increased volume in the right praecuneus which was decreased in the entire cohort.

The genu is associated with flexibility during reward-based learning (Chau et al., 2018), and has not been previously reported as abnormal in AN (Barona et al., 2019; Hayes et al., 2015). PET studies in humans with AN found significantly increased serotonergic receptor activity within the subgenual cingulate, within the region of the genu (Bailer et al., 2007). The genu also bridges the gap between the limbs of the internal capsules, which have been associated in AN (Gaudio et al., 2017; Miles et al., 2019; Phillipou et al., 2018) and have been prime targets for deep-brain stimulation in recovery protocols (Lipsman et al., 2013; McLaughlin et al., 2013; Park et al., 2018). Volumetric increase seen in the genu or internal capsule may reflect alterations in reward-based learning, and development of attentional biases to disorder-salient stimuli (Miles et al., 2019). Age-related changes between adult populations compared with all collated data in AN led to a significant effect in the ACC, widely reported throughout the AN literature. The central location of the anterior cingulate cortex within the brain reflects its functional role as a complex information processing hub, performing roles in

cognitive and emotional control, such as the processing of universal emotions, conflict monitoring, appraisal of emotional stimuli, error prediction, modulation of risk/fear-mediated behaviour and conditioning (Allman et al., 2001; Etkin et al., 2006; Margulies et al., 2007; Pessoa, 2008; Saunders et al., 2017; Shackman et al., 2011; Stevens et al., 2011).

Contrasting our findings, previous work into the ACC in those with AN show reduction in volume (Hayes et al., 2015; McCormick et al., 2008; Mührlau et al., 2007) and inconsistent recovery success of ACC thickness following treatment protocols (Martin Monzon et al., 2017). fMRI studies in AN find increased activity of the ACC, particularly during set-shifting tasks assessing cognitive flexibility, which was associated with traits of perfectionism, elevated monitoring and intolerance of uncertainty (Geisler et al., 2017). The ACC is also densely connected to the paracentral lobules which together play important roles in functional integration (Hagmann et al., 2008). Development of the ACC appears to be particularly important during adolescence, and participates in significant structural reorganization (Ho et al., 2017; Lichenstein et al., 2016). Transformation of the ACC during adolescence may provide an explanation as to why no ACC clusters were visualised when testing the entire AN cohort which included adolescent studies. Regarding age-related OFC findings, structural abnormality is not as pronounced when comparing adults with AN to the entire dataset. It may be possible that adolescents experience bilateral alteration of the OFC while adults with AN experience alteration of the right OFC.

In summary, those with AN exhibit significant structural increase in executive and emotional brain regions, as well as decreases more posteriorly located and implicated in basic visual/somatosensation integration and cognition. Following the logic that increased volume is attributed to increased activity/usage and vice versa, those with AN may be susceptible to increased monitoring and vigilant behaviour as well as working memory and visual impairments. Increase of the parahippocampal gyrus in this study is a particularly robust finding, and may reflect impaired or overgeneralised recall of autobiographical memories. Reduction of volume in regions pertinent to somatosensation and inhibition control may contribute to pathologically significant conflict avoidance and decreased empathy seen in AN (Bach et al., 2014; Konstantakopoulos et al., 2020). A lack of consistently reported anatomical regions across literature in those with ASD renders this review unable to confirm any overlapping differences in structure. Aside from VBM-related findings, a lack of any discernible shared neuroanatomical aberrance between both conditions is likely due to the symptomatic and diagnostic heterogeneity

presented by ASD, as well as condition-related increase in prevalence for a variety of psychiatric comorbidities.

## 4.1 | Limitations

Certain limitations must be considered alongside the results of this study. Conducting meta-analyses on a large scale increases the risk of methodological heterogeneity interfering with validity of findings. Individual studies utilised different scanning parameters and statistical threshold specifications, which are difficult to standardise in preparation for analysis. Additionally, we did not examine how variation in anorexic duration of illness may have affected results.

Additionally, we included patients who recovered from AN (RAN) as an additional clinical subgroup. Regardless of excluding the majority of RAN patients, there were approximately 6% of RAN patients that we were unable to remove from data. We confined our analysis to focus on grey matter changes due to limited VBM literature on white matter available.

Lastly, we are unable to determine the direction of causation between aberrant volume and restrictive eating/chronic starvation seen in AN due to cross-sectional analytic methodology. As is often the case with neuroimaging studies, findings within this study do not elaborate on the causal relationship between unusual neuroanatomy and condition. While we suggest that increased volume of the ACC may further contribute to symptoms of AN, we are unable to confirm whether restriction associated with AN instead contributes to increased ACC volume.

## 5 | CONCLUSION

This study presents the largest to-date meta-analysis of collated MRI coordinate literature in AN and ASD populations. Aggregating all available VBM studies of both conditions demonstrates significantly altered neuroanatomy in those with AN when compared with healthy individuals, but no significant effects in those with ASD, and thus no condition-related structural overlap. Lack of significant findings in ASD contrasts a number of previous associated regions in studies, and suggests an inconsistency in the neuroanatomy associated with ASD. Clusters of increased volume in AN occurred in regions attributed to executive function, decision-making and conflict monitoring, as well as consolidation of episodic and autobiographical memories (MFG/OFC/MTL). Adult-only AN studies noted a significant effect in the ACC and genu, which may

reflect impaired conflict monitoring, flexibility, reward-based learning and processing of emotional stimuli. This meta-analysis provides updated information pertaining to neuroanatomical structure associated with AN and ASD, as well as novel findings concerning associated areas of increased volume in AN. Our findings corroborate extensive evidence that psychophysiological symptoms exhibited in with AN are reflected in neuroanatomical structure, and brain regions implicated in this review may serve as effective benchmarks for the detection, diagnosis and treatment of AN.

## ACKNOWLEDGEMENTS

I would like to express my thanks and sincere gratitude to the Northwood Charitable Trust for funding my PhD studentship and subsequent research. I would also like to extend my thanks to Dr Kate Tchanturia for her preparation of this special edition of the European Eating Disorder Review focussing on ASD and eating disorders. The studentship driving this research has been awarded by the Northwood Charitable Trust (RG15207).

## CONFLICT OF INTEREST

The authors have no conflicts of interest to report.

## DATA AVAILABILITY STATEMENT

The data that supports the findings of this study are available in the supplementary material of this article.

## REFERENCES

- Aguirre, G. K., Zarahn, E., & D'Esposito, M. (1998). An area within human ventral cortex sensitive to "building" stimuli: Evidence and implications. *Neuron*, *21*(2), 373–383.
- Akimoto, Y., Sugiura, M., Yomogida, Y., Miyauchi, C. M., Miyazawa, S., & Kawashima, R. (2014). Irony comprehension: Social conceptual knowledge and emotional response. *Human Brain Mapping*, *35*(4), 1167–1178.
- Allman, J. M., Hakeem, A., Erwin, J. M., Nimchinsky, E., & Hof, P. (2001). The anterior cingulate cortex: The evolution of an interface between emotion and cognition. *Annals of the New York Academy of Sciences*, *935*(1), 107–117.
- American Psychiatric Association. (2000). *Diagnostic criteria from DSM-IV-tr*. American Psychiatric Pub.
- Amianto, F., Caroppo, P., D'Agata, F., Spalatro, A., Lavagnino, L., Caglio, M., Righi, D., Bergui, M., Abbate-Daga, G., Rigardetto, R., Mortara, P., & Fassino, S. (2013). Brain volumetric abnormalities in patients with anorexia and bulimia nervosa: A voxel-based morphometry study. *Psychiatry Research: Neuroimaging*, *213*(3), 210–216.
- Ashburner, J., & Friston, K. J. (2001). Why voxel-based morphometry should be used. *NeuroImage*, *14*(6), 1238–1243.
- Australian, R. (2005). New Zealand college of psychiatrists clinical practice guidelines team for anorexia nervosa. Australian and New Zealand clinical practice guidelines for the treatment of anorexia nervosa. *Focus*, *3*(4), 618.
- Bach, D. R., Guitart-Masip, M., Packard, P. A., Miró, J., Falip, M., Fuentemilla, L., & Dolan, R. J. (2014). Human hippocampus arbitrates approach-avoidance conflict. *Current Biology*, *24*(5), 541–547.
- Bailer, U. F., Frank, G. K., Henry, S. E., Price, J. C., Meltzer, C. C., Mathis, C. A., Wagner, A., Thornton, L., Hoge, J., Ziolkowski, S. K., Becker, C. R., McConaha, C. W., & Kaye, W. H. (2007). Exaggerated 5-HT<sub>1A</sub> but normal 5-HT<sub>2A</sub> receptor activity in individuals ill with anorexia nervosa. *Biological Psychiatry*, *61*(9), 1090–1099.
- Bär, K. J., de la Cruz, F., Berger, S., Schultz, C. C., & Wagner, G. (2015). Structural and functional differences in the cingulate cortex relate to disease severity in anorexia nervosa. *Journal of Psychiatry & Neuroscience: JPN*, *40*(4), 269.
- Barona, M., Brown, M., Clark, C., Frangou, S., White, T., & Micali, N. (2019). White matter alterations in anorexia nervosa: Evidence from a voxel-based meta-analysis. *Neuroscience & Biobehavioral Reviews*, *100*, 285–295.
- Baron-Cohen, S., Tager-Flusberg, H., & Lombardo, M. (Eds.). (2013). *Understanding other minds: Perspectives from developmental social neuroscience*. Oxford university press.
- Baron-Cohen, S., Wheelwright, S., Hill, J., Raste, Y., & Plumb, I. (2001). The "reading the Mind in the eyes" test revised version: A study with normal adults, and adults with asperger syndrome or high-functioning autism. *The Journal of Child Psychology and Psychiatry and Allied Disciplines*, *42*(2), 241–251.
- Björnsdotter, M., Davidovic, M., Karjalainen, L., Starck, G., Olausson, H., & Wentz, E. (2018). Grey matter correlates of autistic traits in women with anorexia nervosa. *Journal of Psychiatry & Neuroscience: JPN*, *43*(2), 79.
- Boccia, M., Teghil, A., & Guariglia, C. (2019). Looking into recent and remote past: Meta-analytic evidence for cortical reorganization of episodic autobiographical memories. *Neuroscience & Biobehavioral Reviews*, *107*, 84–95.
- Boddaert, N., Chabane, N., Gervais, H., Good, C. D., Bourgeois, M., Plumet, M. H., Barthelemy, C., Mouren, M. C., Artiges, E., Samson, Y., Brunelle, F., Frackowiak, R. S. J., & Zilbovicius, M. (2004). Superior temporal sulcus anatomical abnormalities in childhood autism: A voxel-based morphometry MRI study. *NeuroImage*, *23*(1), 364–369.
- Boghi, A., Sterpone, S., Sales, S., D'Agata, F., Bradac, G. B., Zullo, G., & Munno, D. (2011). In vivo evidence of global and focal brain alterations in anorexia nervosa. *Psychiatry Research: Neuroimaging*, *192*(3), 154–159.
- Bomba, M., Marfone, M., Brivio, E., Oggiano, S., Broggi, F., Neri, F., & Nacinovich, R. (2014). Autobiographical memory in adolescent girls with anorexia nervosa. *European Eating Disorders Review*, *22*(6), 479–486.
- Bonilha, L., Cendes, F., Rorden, C., Eckert, M., Dalgarrondo, P., Li, L. M., & Steiner, C. E. (2008). Gray and white matter imbalance—typical structural abnormality underlying classic autism? *Brain & Development*, *30*(6), 396–401.
- Bougeard, C., Picarel-Blanchot, F., Schmid, R., Campbell, R., & Buitelaar, J. (2021). Prevalence of autism spectrum disorder and Co-morbidities in children and adolescents: A systematic literature review. *Frontiers in Psychiatry*, 1834.
- Brieber, S., Neufang, S., Bruning, N., Kamp-Becker, I., Remschmidt, H., Herpertz-Dahlmann, B., Fink, G. R., & Konrad, K. (2007).

- Structural brain abnormalities in adolescents with autism spectrum disorder and patients with attention deficit/hyperactivity disorder. *Journal of Child Psychology and Psychiatry*, 48(12), 1251–1258.
- Brooks, S. J., Barker, G. J., O'Daly, O. G., Brammer, M., Williams, S. C., Benedict, C., Schiöth, H. B., Treasure, J., & Campbell, I. C. (2011). Restraint of appetite and reduced regional brain volumes in anorexia nervosa: A voxel-based morphometric study. *BMC Psychiatry*, 11(1), 1.
- Burkert, N. T., Koschutnig, K., Ebner, F., & Freidl, W. (2015). Structural hippocampal alterations, perceived stress, and coping deficiencies in patients with anorexia nervosa. *International Journal of Eating Disorders*, 48(6), 670–676.
- Cai, J., Hu, X., Guo, K., Yang, P., Situ, M., & Huang, Y. (2018). Increased left inferior temporal gyrus was found in both low function autism and high function autism. *Frontiers in Psychiatry*, 9, 542.
- Cakir, J., Frye, R. E., & Walker, S. J. (2020). The lifetime social cost of autism: 1990–2029. *Research in Autism Spectrum Disorders*, 72, 101502.
- Calderoni, S., Retico, A., Biagi, L., Tancredi, R., Muratori, F., & Tosetti, M. (2012). Female children with autism spectrum disorder: An insight from mass-univariate and pattern classification analyses. *NeuroImage*, 59(2), 1013–1022.
- Cascino, G., Canna, A., Monteleone, A. M., Russo, A. G., Prinster, A., Aiello, M., Esposito, F., Di Salle, F., & Monteleone, P. (2020). Cortical thickness, local gyrification index and fractal dimensionality in people with acute and recovered Anorexia Nervosa and in people with Bulimia Nervosa. *Psychiatry Research: Neuroimaging*, 299, 111069.
- Castellon, P., Sudres, J. L., & Voltzenlogel, V. (2020). Self-defining memories in female patients with anorexia nervosa. *European Eating Disorders Review*, 28(5), 513–524.
- Castro-Fornieles, J., Bargalló, N., Lázaro, L., Andrés, S., Falcon, C., Plana, M. T., & Junqué, C. (2009). A cross-sectional and follow-up voxel-based morphometric MRI study in adolescent anorexia nervosa. *Journal of Psychiatric Research*, 43(3), 331–340.
- Cauda, F., Geda, E., Sacco, K., D'Agata, F., Duca, S., Geminiani, G., & Keller, R. (2011). Grey matter abnormality in autism spectrum disorder: An activation likelihood estimation meta-analysis study. *Journal of Neurology, Neurosurgery & Psychiatry*, 82(12), 1304–1313.
- Chau, B. K., Jarvis, H., Law, C. K., & Chong, T. T. (2018). Dopamine and reward: A view from the prefrontal cortex. *Behavioural Pharmacology*, 29(7), 569–583.
- Cheng, Y., Chou, K. H., Fan, Y. T., & Lin, C. P. (2011). ANS: Aberrant neurodevelopment of the social cognition network in adolescents with autism spectrum disorders. *PLoS One*, 6(4), e18905.
- Corbett, B. A., Carmean, V., Ravizza, S., Wendelken, C., Henry, M. L., Carter, C., & Rivera, S. M. (2009). A functional and structural study of emotion and face processing in children with autism. *Psychiatry Research: Neuroimaging*, 173(3), 196–205.
- Craig, M., Zaman, S. H., Daly, E. M., Cutter, W. J., Robertson, D. M., Hallahan, B., Toal, F., Reed, S., Ambikopathy, A., Brammer, M., Murphy, C. M., & Murphy, D. G. M. (2007). Women with autistic-spectrum disorder: Magnetic resonance imaging study of brain anatomy. *The British Journal of Psychiatry*, 191(3), 224–228.
- D'Agata, F., Caroppo, P., Amianto, F., Spalatro, A., Caglio, M. M., Bergui, M., Lavagnino, L., Righi, D., Abbate-Daga, G., Pinessi, L., Mortara, P., & Fassino, S. (2015). Brain correlates of alexithymia in eating disorders: A voxel-based morphometry study. *Psychiatry and Clinical Neurosciences*, 69(11), 708–716.
- David, N., Schultz, J., Milne, E., Schunke, O., Schöttle, D., Münchau, A., Siegel, M., Vogeley, K., & Engel, A. K. (2014). Right temporoparietal gray matter predicts accuracy of social perception in the autism spectrum. *Journal of Autism and Developmental Disorders*, 44(6), 1433–1446.
- DeRamus, T. P., & Kana, R. K. (2015). Anatomical likelihood estimation meta-analysis of grey and white matter anomalies in autism spectrum disorders. *NeuroImage: Clinical*, 7, 525–536.
- D'Mello, A. M., Crocetti, D., Mostofsky, S. H., & Stoodley, C. J. (2015). Cerebellar gray matter and lobular volumes correlate with core autism symptoms. *NeuroImage: Clinical*, 7, 631–639.
- Duerden, E. G., Mak-Fan, K. M., Taylor, M. J., & Roberts, S. W. (2012). Regional differences in grey and white matter in children and adults with autism spectrum disorders: An activation likelihood estimate (ALE) meta-analysis. *Autism Research*, 5(1), 49–66.
- Ebisch, S. J., Gallese, V., Willems, R. M., Mantini, D., Groen, W. B., Romani, G. L., Buitelaar, J. K., & Bekkering, H. (2011). Altered intrinsic functional connectivity of anterior and posterior insula regions in high-functioning participants with autism spectrum disorder. *Human Brain Mapping*, 32(7), 1013–1028.
- Ecker, C., Ronan, L., Feng, Y., Daly, E., Murphy, C., Ginestet, C. E., Brammer, M., Fletcher, P. C., Bullmore, E. T., Suckling, J., Baron-Cohen, S., Williams, S., Loth, E., Murphy, D. G. M., Bailey, A. J., Baron-Cohen, S., Bolton, P. F., Bullmore, E. T., Carrington, S., ... Williams, S. C. (2013). Intrinsic gray-matter connectivity of the brain in adults with autism spectrum disorder. *Proceedings of the National Academy of Sciences*, 110(32), 13222–13227.
- Eickhoff, S. B., Laird, A. R., Grefkes, C., Wang, L. E., Zilles, K., & Fox, P. T. (2009). Coordinate-based activation likelihood estimation meta-analysis of neuroimaging data: A random-effects approach based on empirical estimates of spatial uncertainty. *Human Brain Mapping*, 30(9), 2907–2926.
- Ekstrom, A. D., Arnold, A. E., & Iaria, G. (2014). A critical review of the allocentric spatial representation and its neural underpinnings: Toward a network-based perspective. *Frontiers in Human Neuroscience*, 8, 803.
- Elsabbagh, M., Divan, G., Koh, Y. J., Kim, Y. S., Kauchali, S., Marcín, C., Montiel-Nava, C., Patel, V., Paula, C. S., Wang, C., Yasamy, M. T., & Fombonne, E. (2012). Global prevalence of autism and other pervasive developmental disorders. *Autism Research*, 5(3), 160–179.
- Etkin, A., Egner, T., Peraza, D. M., Kandel, E. R., & Hirsch, J. (2006). Resolving emotional conflict: A role for the rostral anterior cingulate cortex in modulating activity in the amygdala. *Neuron*, 51(6), 871–882.
- Floris, D. L., Lai, M. C., Auer, T., Lombardo, M. V., Ecker, C., Chakrabarti, B., Wheelwright, S. J., Bullmore, E. T., Murphy, D. G., Baron-Cohen, S., & Suckling, J. (2016). Atypically rightward cerebral asymmetry in male adults with autism stratifies individuals with and without language delay. *Human Brain Mapping*, 37(1), 230–253, 91.

- Fonville, L., Giampietro, V., Williams, S. C., Simmons, A., & Tchanturia, K. (2014). Alterations in brain structure in adults with anorexia nervosa and the impact of illness duration. *Psychological Medicine*, *44*(9), 1965–1975.
- Foster, N. E., Doyle-Thomas, K. A., Tryfon, A., Ouimet, T., Anagnostou, E., Evans, A. C., Zwaigenbaum, L., Lerch, J. P., Lewis, J. D., Hyde, K. L., & NeuroDevNet, A. S. (2015). Structural gray matter differences during childhood development in autism spectrum disorder: A multimetric approach. *Pediatric Neurology*, *53*(4), 350–359.
- Frank, G. K., Shott, M. E., Hagman, J. O., & Mittal, V. A. (2013). Alterations in brain structures related to taste reward circuitry in ill and recovered anorexia nervosa and in bulimia nervosa. *American Journal of Psychiatry*, *170*(10), 1152–1160.
- Friederich, H. C., Walther, S., Bendszus, M., Biller, A., Thomann, P., Zeigermann, S., Katus, T., Brunner, R., Zastrow, A., & Herzog, W. (2012). Grey matter abnormalities within cortico-limbic-striatal circuits in acute and weight-restored anorexia nervosa patients. *NeuroImage*, *59*(2), 1106–1113.
- Fuglset, T. S., Endestad, T., Hilland, E., Bang, L., Tamnes, C. K., Landrø, N. I., & Rø, Ø. (2016). Brain volumes and regional cortical thickness in young females with anorexia nervosa. *BMC psychiatry*, *16*(1), 1–8.
- Fujisawa, T. X., Yatsuga, C., Mabe, H., Yamada, E., Masuda, M., & Tomoda, A. (2015). Anorexia nervosa during adolescence is associated with decreased gray matter volume in the inferior frontal gyrus. *PLoS One*, *10*(6), e0128548.
- Gaudio, S., Nocchi, F., Franchin, T., Genovese, E., Cannatà, V., Longo, D., & Fariello, G. (2011). Gray matter decrease distribution in the early stages of Anorexia Nervosa restrictive type in adolescents. *Psychiatry Research: Neuroimaging*, *191*(1), 24–30. [autism papers].
- Gaudio, S., Olivo, G., Zobel, B. B., & Schiöth, H. B. (2018). Altered cerebellar–insular–parietal–cingular subnetwork in adolescents in the earliest stages of anorexia nervosa: A network-based statistic analysis. *Translational Psychiatry*, *8*(1), 1–0.
- Gaudio, S., Quattrocchi, C. C., Piervincenzi, C., Zobel, B. B., Montecchi, F. R., Dakanalis, A., Riva, G., & Carducci, F. (2017). White matter abnormalities in treatment-naïve adolescents at the earliest stages of anorexia nervosa: A diffusion tensor imaging study. *Psychiatry Research: Neuroimaging*, *266*, 138–145.
- Geisler, D., Ritschel, F., King, J. A., Bernardoni, F., Seidel, M., Boehm, I., Runge, F., Goschke, T., Roessner, V., Smolka, M. N., & Ehrlich, S. (2017). Increased anterior cingulate cortex response precedes behavioural adaptation in anorexia nervosa. *Scientific Reports*, *7*, 42066.
- Georgiades, S., Szatmari, P., & Boyle, M. (2013). Importance of studying heterogeneity in autism. *Neuropsychiatry*, *3*(2), 123–125.
- Greimel, E., Nehr Korn, B., Schulte-Rüther, M., Fink, G. R., Nickl-Jockschat, T., Herpertz-Dahlmann, B., Konrad, K., & Eickhoff, S. B. (2013). Changes in grey matter development in autism spectrum disorder. *Brain Structure and Function*, *218*(4), 929–942.
- Gröne, M., Dyck, M., Koush, Y., Bergert, S., Mathiak, K. A., Alawi, E. M., Elliott, M., & Mathiak, K. (2015). Upregulation of the rostral anterior cingulate cortex can alter the perception of emotions: fMRI-based neurofeedback at 3 and 7 T. *Brain Topography*, *28*(2), 197–207.
- Hagmann, P., Cammoun, L., Gigandet, X., Meuli, R., Honey, C. J., Wedeen, V. J., & Sporns, O. (2008). Mapping the structural core of human cerebral cortex. *PLoS Biology*, *6*(7), e159–162.
- Hanaie, R., Mohri, I., Kagitani-Shimono, K., Tachibana, M., Matsuzaki, J., Hirata, I., Nagatani, F., Watanabe, Y., Fujita, N., & Taniike, M. (2016). White matter volume in the brainstem and inferior parietal lobule is related to motor performance in children with autism spectrum disorder: A voxel-based morphometry study. *Autism Research*, *9*(9), 981–992.
- Hayes, D. J., Lipsman, N., Chen, D. Q., Woodside, D. B., Davis, K. D., Lozano, A. M., & Hodaie, M. (2015). Subcallosal cingulate connectivity in anorexia nervosa patients differs from healthy controls: A multi-tensor tractography study. *Brain Stimulation*, *8*(4), 758–768.
- Heaton, R. K., Chelune, G. J., Talley, J. L., Kay, G. G., Curtis, G., Curtiss, G., Heaton, R., Chelune, G., Talley, J., & Kay, G. (1993). *Wisconsin Card Sorting Test (WCST)—manual revised and expanded*.
- Ho, T. C., Sacchet, M. D., Connolly, C. G., Margulies, D. S., Tymofiyeva, O., Paulus, M. P., Simmons, A. N., Gotlib, I. H., & Yang, T. T. (2017). Inflexible functional connectivity of the dorsal anterior cingulate cortex in adolescent major depressive disorder. *Neuropsychopharmacology*, *42*(12), 2434–2445.
- Hoek, H. W. (2006). Incidence, prevalence and mortality of anorexia nervosa and other eating disorders. *Current Opinion in Psychiatry*, *19*(4), 389–394.
- Horndasch, S., Roesch, J., Forster, C., Dörfler, A., Lindsiepe, S., Heinrich, H., Graap, H., Moll, G. H., & Kratz, O. (2018). Neural processing of food and emotional stimuli in adolescent and adult anorexia nervosa patients. *PLoS One*, *13*(3), e0191059.
- Huber, J., Salatsch, C., Ingenerf, K., Schmid, C., Maatouk, I., Weisbrod, M., Herzog, W., Friederich, H. C., & Nikendei, C. (2015). Characteristics of disorder-related autobiographical memory in acute anorexia nervosa patients. *European Eating Disorders Review*, *23*(5), 379–389.
- Huke, V., Turk, J., Saeidi, S., Kent, A., & Morgan, J. F. (2013). Autism spectrum disorders in eating disorder populations: A systematic review. *European Eating Disorders Review*, *21*(5), 345–351.
- Hyde, K. L., Samson, F., Evans, A. C., & Mottron, L. (2010). Neuroanatomical differences in brain areas implicated in perceptual and other core features of autism revealed by cortical thickness analysis and voxel-based morphometry. *Human Brain Mapping*, *31*(4), 556–566.1.
- Itahashi, T., Yamada, T., Nakamura, M., Watanabe, H., Yamagata, B., Jimbo, D., Shioda, S., Kuroda, M., Toriizuka, K., Kato, N., & Hashimoto, R. (2015). Linked alterations in gray and white matter morphology in adults with high-functioning autism spectrum disorder: A multimodal brain imaging study. *NeuroImage: Clinical*, *7*, 155–169.
- Joos, A., Hartmann, A., Glauche, V., Perlov, E., Unterbrink, T., Saum, B., Tüscher, O., Tebartz van Elst, L., & Zeeck, A. (2011). Grey matter deficit in long-term recovered anorexia nervosa patients. *European Eating Disorders Review*, *19*(1), 59–63.
- Kappou, K., Ntougia, M., Kourtesi, A., Panagouli, E., Vlachopapadopoulou, E., Michalacos, S., Gonidakis, F., Mastorakos, G., Psaltopoulou, T., Tsolia, M., Bacopoulou, F., Sergentanis,



- T.N., & Tsitsika, A. (2021). Neuroimaging findings in adolescents and young adults with anorexia nervosa: A systematic review. *Children*, *8*(2), 137.
- Karlsson, L., Råstam, M., & Wentz, E. (2013). The Swedish Eating Assessment for Autism spectrum disorders (SWEAA)—validation of a self-report questionnaire targeting eating disturbances within the autism spectrum. *Research in Developmental Disabilities*, *34*(7), 2224–2233.
- Kerr-Gaffney, J., Harrison, A., & Tchanturia, K. (2019). Cognitive and affective empathy in eating disorders: A systematic review and meta-analysis. *Frontiers in Psychiatry*, *10*, 102.
- Kim, K. R., Ku, J., Lee, J. H., Lee, H., & Jung, Y. C. (2012). Functional and effective connectivity of anterior insula in anorexia nervosa and bulimia nervosa. *Neuroscience Letters*, *521*(2), 152–157.
- Kohmura, K., Adachi, Y., Tanaka, S., Katayama, H., Imaeda, M., Kawano, N., Nishioka, K., Ando, M., Iidaka, T., & Ozaki, N. (2017). Regional decrease in gray matter volume is related to body dissatisfaction in anorexia nervosa. *Psychiatry Research: Neuroimaging*, *267*, 51–58.
- Kojima, M., Yassin, W., Owada, K., Aoki, Y., Kuwabara, H., Nat-subori, T., Iwashiro, N., Gono, W., Takao, H., Kasai, K., Abe, O., Kano, Y., & Yamasue, H. (2019). Neuroanatomical correlates of advanced paternal and maternal age at birth in autism spectrum disorder. *Cerebral Cortex*, *29*(6), 2524–2532.
- Konstantakopoulos, G., Ioannidi, N., Patrikelis, P., & Gonidakis, F. (2020). Empathy, mentalizing, and cognitive functioning in anorexia nervosa and bulimia nervosa. *Social Neuroscience*, *15*(4), 477–488.
- Kosaka, H., Omori, M., Munesue, T., Ishitobi, M., Matsumura, Y., Takahashi, T., Narita, K., Murata, T., Saito, D. N., Uchiyama, H., Morita, T., Kikuchi, M., Mizukami, K., Okazawa, H., Sadato, N., & Wada, Y. (2010). Smaller insula and inferior frontal volumes in young adults with pervasive developmental disorders. *NeuroImage*, *50*(4), 1357–1363.
- Kurth, F., Narr, K. L., Woods, R. P., O'Neill, J., Alger, J. R., Caplan, R., McCracken, J. T., Toga, A. W., & Levitt, J. G. (2011). Diminished gray matter within the hypothalamus in autism disorder: A potential link to hormonal effects? *Biological Psychiatry*, *70*(3), 278–282.
- Lancaster J. L., & Martinez M. J. (2011). *Multi-image analysis GUI (Mango)*. Available at: [ric.uthscsa.edu/mango/](http://ric.uthscsa.edu/mango/)
- Lavagnino, L., Mwangi, B., Cao, B., Shott, M. E., Soares, J. C., & Frank, G. K. (2018). Cortical thickness patterns as state biomarker of anorexia nervosa. *International Journal of Eating Disorders*, *51*(3), 241–249.
- Lavelle, T. A., Weinstein, M. C., Newhouse, J. P., Munir, K., Kuhlthau, K. A., & Prosser, L. A. (2014). Economic burden of childhood autism spectrum disorders. *Pediatrics*, *133*(3), e520–e529.
- Lázaro, L., Andrés, S., Calvo, A., Cullell, C., Moreno, E., Plana, M. T., Falcón, C., Bargalló, N., & Castro-Fornieles, J. (2013). Normal gray and white matter volume after weight restoration in adolescents with anorexia nervosa. *International Journal of Eating Disorders*, *46*(8), 841–848.
- Lee, S., Kim, K. R., Ku, J., Lee, J. H., Namkoong, K., & Jung, Y. C. (2014). Resting-state synchrony between anterior cingulate cortex and precuneus relates to body shape concern in anorexia nervosa and bulimia nervosa. *Psychiatry Research: Neuroimaging*, *221*(1), 43–48.
- Leppanen, J., Sedgewick, F., Cardi, V., Treasure, J., & Tchanturia, K. (2019). Cortical morphometry in anorexia nervosa: An out-of-sample replication study. *European Eating Disorders Review*, *27*(5), 507–520.
- Li, Q., Becker, B., Jiang, X., Zhao, Z., Zhang, Q., Yao, S., & Kendrick, K. M. (2019). Decreased interhemispheric functional connectivity rather than corpus callosum volume as a potential biomarker for autism spectrum disorder. *Cortex*, *119*, 258–266.
- Lichenstein, S. D., Verstynen, T., & Forbes, E. E. (2016). Adolescent brain development and depression: A case for the importance of connectivity of the anterior cingulate cortex. *Neuroscience & Biobehavioral Reviews*, *70*, 271–287, 3.
- Lim, L., Chantiluke, K., Cubillo, A. I., Smith, A. B., Simmons, A., Mehta, M. A., & Rubia, K. (2015). Disorder-specific grey matter deficits in attention deficit hyperactivity disorder relative to autism spectrum disorder. *Psychological Medicine*, *45*(5), 965–976.
- Lin, H. Y., Ni, H. C., Lai, M. C., Tseng, W. Y., & Gau, S. S. (2015). Regional brain volume differences between males with and without autism spectrum disorder are highly age-dependent. *Molecular Autism*, *6*(1), 1–8.
- Lipsman, N., Woodside, D. B., Giacobbe, P., Hamani, C., Carter, J. C., Norwood, S. J., Sutandar, K., Staab, R., Elias, G., Lyman, C. H., Smith, G. S., & Lozano, A. M. (2013). Subcallosal cingulate deep brain stimulation for treatment-refractory anorexia nervosa: A phase 1 pilot trial. *The Lancet*, *381*(9875), 1361–1370.
- Liu, B., Liu, J., Ju, Y., Wang, M., Liu, T., Zhang, Y., Li, L., Potenza, M., & Barron, D. S. (2019). Altered brain function in anorexia nervosa and bulimia nervosa: A hierarchical series of task-based fMRI meta-analyses. *bioRxiv*, 550301.
- Liu, J., Yao, L., Zhang, W., Xiao, Y., Liu, L., Gao, X., Shah, C., Li, S., Tao, B., Gong, Q., & Lui, S. (2017). Gray matter abnormalities in pediatric autism spectrum disorder: A meta-analysis with signed differential mapping. *European Child & Adolescent Psychiatry*, *26*(8), 933–945.
- Lombardo, M. V., Barnes, J. L., Wheelwright, S. J., & Baron-Cohen, S. (2007). Self-referential cognition and empathy in autism. *PLoS One*, *2*(9).
- Margulies, D. S., Kelly, A. C., Uddin, L. Q., Biswal, B. B., Castellanos, F. X., & Milham, M. P. (2007). Mapping the functional connectivity of anterior cingulate cortex. *NeuroImage*, *37*(2), 579–588.
- Martin Monzon, B., Henderson, L. A., Madden, S., Macefield, V. G., Touyz, S., Kohn, M. R., Clarke, S., Foroughi, N., & Hay, P. (2017). Grey matter volume in adolescents with anorexia nervosa and associated eating disorder symptoms. *European Journal of Neuroscience*, *46*(7), 2297–2307.
- McAlonan, G. M., Li, Q., Cheung, C., Wei, R., Chua, S. E., Sham, P. C., & Wu, E. X. (2009). Evidence that prenatal infection is a risk factor for brain and behaviour changes relevant to schizophrenia and autism. *InConference Abstract: 41st European Brain and Behaviour Society Meeting*, *8*(09) 228. <https://doi.org/10.3389/conf.neuro2009>
- McCormick, L. M., Keel, P. K., Brumm, M. C., Bowers, W., Swayze, V., Andersen, A., & Andreasen, N. (2008). Implications of starvation-induced change in right dorsal anterior cingulate volume in anorexia nervosa. *International Journal of Eating Disorders*, *41*(7), 602–610.

- McCrory, E. J., Puetz, V. B., Maguire, E. A., Mechelli, A., Palmer, A., Gerin, M. I., Kelly, P. A., Koutoufa, I., & Viding, E. (2017). Autobiographical memory: A candidate latent vulnerability mechanism for psychiatric disorder following childhood maltreatment. *The British Journal of Psychiatry*, *211*(4), 216–222.
- McLaughlin, N. C., Didie, E. R., Machado, A. G., Haber, S. N., Eskandar, E. N., & Greenberg, B. D. (2013). Improvements in anorexia symptoms after deep brain stimulation for intractable obsessive-compulsive disorder. *Biological Psychiatry*, *73*(9), e29–e31.
- Mechelli, A., Price, C. J., Friston, K. J., & Ashburner, J. (2005). Voxel-based morphometry of the human brain: Methods and applications. *Current Medical Imaging*, *1*(2), 105–113.
- Mengotti, P., D'Agostini, S., Terlevic, R., De Colle, C., Biasizzo, E., Londero, D., Ferro, A., Rambaldelli, G., Balestrieri, M., Zanini, S., Fabbro, F., Molteni, M., & Brambilla, P. (2011). Altered white matter integrity and development in children with autism: A combined voxel-based morphometry and diffusion imaging study. *Brain Research Bulletin*, *84*(2), 189–195.
- Miles, A. E., Kaplan, A. S., French, L., & Voineskos, A. N. (2019). White matter microstructure in women with acute and remitted anorexia nervosa: An exploratory neuroimaging study. *Brain imaging and behavior*, 1–9.
- Mueller, S., Keeser, D., Samson, A. C., Kirsch, V., Blautzik, J., Grothe, M., Erat, O., Hegenloh, M., Coates, U., Reiser, M. F., Hennig-Fast, K., & Meindl, T. (2013). Convergent findings of altered functional and structural brain connectivity in individuals with high functioning autism: A multimodal MRI study. *PLoS One*, *8*(6), e67329.
- Mühlau, M., Gaser, C., Ilg, R., Conrad, B., Leibl, C., Cebulla, M. H., Backmund, H., Gerlinghoff, M., Lommer, P., Schnebel, A., & Wohlschläger, A. M. (2007). Gray matter decrease of the anterior cingulate cortex in anorexia nervosa. *American Journal of Psychiatry*, *164*(12), 1850–1857.
- Mul, C. L., Stagg, S. D., Herbelin, B., & Aspell, J. E. (2018). The feeling of me feeling for you: Interoception, alexithymia and empathy in autism. *Journal of Autism and Developmental Disorders*, *48*(9), 2953–2967.
- Ni, H. C., Lin, H. Y., Tseng, W. Y., Chiu, Y. N., Wu, Y. Y., Tsai, W. C., & Gau, S. S. (2018). Neural correlates of impaired self-regulation in male youths with autism spectrum disorder: A voxel-based morphometry study. *Progress in neuro-psychopharmacology and biological psychiatry*, *82*, 233–241.
- Nickel, K., Joos, A., Tebartz van Elst, L., Matthis, J., Holovics, L., Endres, D., Zeeck, A., Hartmann, A., Tüscher, O., & Maier, S. (2018). Recovery of cortical volume and thickness after remission from acute anorexia nervosa. *International Journal of Eating Disorders*, *51*(9), 1056–1069.
- Nickl-Jockschat, T., Habel, U., Maria Michel, T., Manning, J., Laird, A. R., Fox, P. T., Schneider, F., & Eickhoff, S. B. (2012). Brain structure anomalies in autism spectrum disorder—a meta-analysis of VBM studies using anatomic likelihood estimation. *Human Brain Mapping*, *33*(6), 1470–1489.
- Oldershaw, A., Treasure, J., Hambrook, D., Tchanturia, K., & Schmidt, U. (2011). Is anorexia nervosa a version of autism spectrum disorders? *European Eating Disorders Review*, *19*(6), 462–474.
- Olivo, G., Solstrand Dahlberg, L., Wiemerslage, L., Swenne, I., Zhukovsky, C., Salonen-Ros, H., Larsson, E.-M., Gaudio, S., Brooks, S. J., & Schiöth, H. B. (2018). Atypical anorexia nervosa is not related to brain structural changes in newly diagnosed adolescent patients. *International Journal of Eating Disorders*, *51*(1), 39–45.
- Osipowicz, K., Bosenbark, D. D., & Patrick, K. E. (2015). Cortical changes across the autism lifespan. *Autism Research*, *8*(4), 379–385.
- Parellada, M., Pina-Camacho, L., Moreno, C., Aleman, Y., Krebs, M. O., Desco, M., Merchán-Naranjo, J., Del Rey-Mejías, A., Boada, L., Llorente, C., Moreno, D., Arango, C., & Janssen, J. (2017). Insular pathology in young people with high-functioning autism and first-episode psychosis. *Psychological Medicine*, *47*(14), 2472–2482.
- Park, R. J., Scaife, J. C., & Aziz, T. Z. (2018). Study protocol: Using deep-brain stimulation, multimodal neuroimaging and neuroethics to understand and treat severe enduring anorexia nervosa. *Frontiers in Psychiatry*, *9*, 24.
- Pereira, A. M., Campos, B. M., Coan, A. C., Pegoraro, L. F., deRezende, T. J., Obeso, I., Dalgalarondo, P., da Costa, J. C., Dreher, J. C., & Cendes, F. (2018). Differences in cortical structure and functional MRI connectivity in high functioning autism. *Frontiers in Neurology*, *9*, 539.
- Pessoa, L. (2008). On the relationship between emotion and cognition. *Nature Reviews Neuroscience*, *9*(2), 148–158.
- Philip, R. C., Dauvermann, M. R., Whalley, H. C., Baynham, K., Lawrie, S. M., & Stanfield, A. C. (2012). A systematic review and meta-analysis of the fMRI investigation of autism spectrum disorders. *Neuroscience & Biobehavioral Reviews*, *36*(2), 901–942.
- Phillipou, A., Carruthers, S. P., Di Biase, M. A., Zalesky, A., Abel, L. A., Castle, D. J., Gurvich, C., & Rossell, S. L. (2018). White matter microstructure in anorexia nervosa. Human brain mapping. *Human Brain Mapping*, *39*(11), 4385–4392.
- Pollatos, O., Herbert, B. M., Berberich, G., Zaudig, M., Krauseneck, T., & Tsakiris, M. (2016). Atypical self-focus effect on interoceptive accuracy in anorexia nervosa. *Frontiers in Human Neuroscience*, *10*, 484.
- Price, J. L., Carmichael, S. T., Carnes, K. M., Clugnet, M. C., Kuroda, M., & Ray, J. P. (1991). *Olfaction: A model system for computational neuroscience* (pp. 101–120). Olfactory input to the prefrontal cortex
- Radeloff, D., Ciaramidaro, A., Siniatchkin, M., Hainz, D., Schlitt, S., Weber, B., Poustka, F., Bölte, S., Walter, H., & Freitag, C. M. (2014). Structural alterations of the social brain: A comparison between schizophrenia and autism. *PLoS One*, *9*(9), e106539.
- Radua, J., Via, E., Catani, M., & Mataix-Cols, D. (2011). Voxel-based meta-analysis of regional white-matter volume differences in autism spectrum disorder versus healthy controls. *Psychological Medicine*, *41*(7), 1539–1550.
- Raznahan, A., Wallace, G. L., Antezana, L., Greenstein, D., Lenroot, R., Thurm, A., Gozzi, M., Spence, S., Martin, A., Swedo, S. E., & Giedd, J. N. (2013). Compared to what? Early brain overgrowth in autism and the perils of population norms. *Biological Psychiatry*, *74*(8), 563–575.
- Retico, A., Giuliano, A., Tancredi, R., Cosenza, A., Apicella, F., Narzisi, A., Biagi, L., Tosetti, M., Muratori, F., & Calderoni, S. (2016). The effect of gender on the neuroanatomy of children with autism spectrum disorders: A support vector machine case-control study. *Molecular Autism*, *7*(1), 1–20.

- Richter, J., Poustka, L., Vomstein, K., Haffner, J., Parzer, P., Stieltjes, B., & Henze, R. (2015). Volumetric alterations in the heteromodal association cortex in children with autism spectrum disorder. *European Psychiatry, 30*(2), 214–220.
- Riva, D., Annunziata, S., Contarino, V., Erbetta, A., Aquino, D., & Bulgheroni, S. (2013). Gray matter reduction in the vermis and CRUS-II is associated with social and interaction deficits in low-functioning children with autistic spectrum disorders: A VBM-DARTEL study. *The Cerebellum, 12*(5), 676–685.
- Riva, G. (2016). Neurobiology of anorexia nervosa: Serotonin dysfunctions link self-starvation with body image disturbances through an impaired body memory. *Frontiers in Human Neuroscience, 10*, 600.
- Rojas, D. C., Peterson, E., Winterrowd, E., Reite, M. L., Rogers, S. J., & Tregellas, J. R. (2006). Regional gray matter volumetric changes in autism associated with social and repetitive behavior symptoms. *BMC Psychiatry, 6*(1), 1–3.
- Rolls, E. T. (2004). The functions of the orbitofrontal cortex. *Brain and Cognition, 55*(1), 11–29.
- Rudolph, K. D., Davis, M. M., Skymba, H. V., Modi, H. H., & Telzer, E. H. (2020). Social experience calibrates neural sensitivity to social feedback during adolescence: A functional connectivity approach. *Developmental Cognitive Neuroscience, 100903*.
- Sato, W., Kochiyama, T., Uono, S., Yoshimura, S., Kubota, Y., Sawada, R., Sakihama, M., & Toichi, M. (2017). Reduced gray matter volume in the social brain network in adults with autism spectrum disorder. *Frontiers in Human Neuroscience, 11*, 395.
- Saunders, B., Lin, H., Milyavskaya, M., & Inzlicht, M. (2017). The emotive nature of conflict monitoring in the medial prefrontal cortex. *International Journal of Psychophysiology, 119*, 31–40.
- Scheel, C., Rotarska-Jagiela, A., Schilbach, L., Lehnhardt, F. G., Krug, B., Voegeley, K., & Tepest, R. (2011). Imaging derived cortical thickness reduction in high-functioning autism: Key regions and temporal slope. *NeuroImage, 58*(2), 391–400.
- Seitz, J., Konrad, K., & Herpertz-Dahlmann, B. (2018). Extend, pathomechanism and clinical consequences of brain volume changes in anorexia nervosa. *Current Neuropharmacology, 16*(8), 1164–1173.
- Seitz, J., Walter, M., Mainz, V., Herpertz-Dahlmann, B., Konrad, K., & von Polier, G. (2015). Brain volume reduction predicts weight development in adolescent patients with anorexia nervosa. *Journal of psychiatric research, 68*, 228–237.
- Shackman, A. J., Salomons, T. V., Slagter, H. A., Fox, A. S., Winter, J. J., & Davidson, R. J. (2011). The integration of negative affect, pain and cognitive control in the cingulate cortex. *Nature Reviews Neuroscience, 12*(3), 154–167.
- Silani, G., Bird, G., Brindley, R., Singer, T., Frith, C., & Frith, U. (2008). Levels of emotional awareness and autism: An fMRI study. *Social Neuroscience, 3*(2), 97–112.
- Stevens, F. L., Hurley, R. A., & Taber, K. H. (2011). Anterior cingulate cortex: Unique role in cognition and emotion. *Journal of Neuropsychiatry and Clinical Neurosciences, 23*(2), 121–125.
- Suchan, B., Busch, M., Schulte, D., Grönermeyer, D., Herpertz, S., & Vocks, S. (2010). Reduction of gray matter density in the extrastriate body area in women with anorexia nervosa. *Behavioural Brain Research, 206*(1), 63–67.
- Titova, O. E., Hjorth, O. C., Schiöth, H. B., & Brooks, S. J. (2013). Anorexia nervosa is linked to reduced brain structure in reward and somatosensory regions: A meta-analysis of VBM studies. *BMC Psychiatry, 13*(1), 1.
- Toal, F., Daly, E. M., Page, L., Deeley, Q., Hallahan, B., Bloemen, O., Cutter, W. J., Brammer, M. J., Curran, S., Robertson, D., Murphy, C., Murphy, K. C., & Murphy, D. G. M. (2010). Clinical and anatomical heterogeneity in autistic spectrum disorder: A structural MRI study. *Psychological Medicine, 40*(7), 1171–1181.
- Tottenham, N., & Galván, A. (2016). Stress and the adolescent brain: Amygdala-prefrontal cortex circuitry and ventral striatum as developmental targets. *Neuroscience & Biobehavioral Reviews, 70*, 217–227.
- Uddin, L. Q., Menon, V., Young, C. B., Ryali, S., Chen, T., Khouzam, A., Minshew, N. J., & Hardan, A. Y. (2011). Multivariate searchlight classification of structural magnetic resonance imaging in children and adolescents with autism. *Biological Psychiatry, 70*(9), 833–841.
- VanOpstal, A. M., Westerink, A. M., Teeuwisse, W. M., vander Geest, M. A., vanFurth, E. F., & vander Grond, J. (2015). Hypothalamic BOLD response to glucose intake and hypothalamic volume are similar in anorexia nervosa and healthy control subjects. *Frontiers in Neuroscience, 9*, 159.
- Waiter, G. D., Williams, J. H., Murray, A. D., Gilchrist, A., Perrett, D. I., & Whiten, A. (2004). A voxel-based investigation of brain structure in male adolescents with autistic spectrum disorder. *NeuroImage, 22*(2), 619–625.
- Waiter, G. D., Williams, J. H., Murray, A. D., Gilchrist, A., Perrett, D. I., & Whiten, A. (2005). Structural white matter deficits in high-functioning individuals with autistic spectrum disorder: A voxel-based investigation. *NeuroImage, 24*(2), 455–461.
- Wang, J., Fu, K., Chen, L., Duan, X., Guo, X., Chen, H., Wu, Q., Xia, W., Wu, L., & Chen, H. (2017). Increased gray matter volume and resting-state functional connectivity in somatosensory cortex and their relationship with autistic symptoms in young boys with autism spectrum disorder. *Frontiers in Physiology, 8*, 588.
- Ward, A. M., Schultz, A. P., Huijbers, W., Van Dijk, K. R., Hedden, T., & Sperling, R. A. (2014). The parahippocampal gyrus links the default-mode cortical network with the medial temporal lobe memory system. *Human Brain Mapping, 35*(3), 1061–1073.
- Warrier, V., Grasby, K. L., Uzevovsky, F., Toro, R., Smith, P., Chakrabarti, B., Khadake, J., Mawbey-Adamson, E., Litterman, N., Hottenga, J. J., Lubke, G., Boomsma, D. I., Martin, N. G., Hatemi, P. K., Medland, S. E., Hinds, D. A., Bourgeron, T., & Baron-Cohen, S. (2018). Genome-wide meta-analysis of cognitive empathy: Heritability, and correlates with sex, neuropsychiatric conditions and cognition. *Molecular Psychiatry, 23*(6), 1402–1409.
- Westwood, H., Stahl, D., Mandy, W., & Tchanturia, K. (2016). The set-shifting profiles of anorexia nervosa and autism spectrum disorder using the Wisconsin card sorting test: A systematic review and meta-analysis. *Psychological Medicine, 46*(9), 1809–1827.
- Westwood, H., & Tchanturia, K. (2017). Autism spectrum disorder in anorexia nervosa: An updated literature review. *Current Psychiatry Reports, 19*(7), 41.
- Wheelwright, S., Baron-Cohen, S., Goldenfeld, N., Delaney, J., Fine, D., Smith, R., Weil, L., & Wakabayashi, A. (2006). Predicting autism spectrum quotient (AQ) from the systemizing quotient-

- revised (SQ-R) and empathy quotient (EQ). *Brain Research*, 1079(1), 47–56.
- Wilson, L. B., Tregellas, J. R., Hagerman, R. J., Rogers, S. J., & Rojas, D. C. (2009). A voxel-based morphometry comparison of regional gray matter between fragile X syndrome and autism. *Psychiatry Research: Neuroimaging*, 174(2), 138–145.
- Xiao, Z., Qiu, T., Ke, X., Xiao, X., Xiao, T., Liang, F., Zou, B., Huang, H., Fang, H., Chu, K., Zhang, J., & Liu, Y. (2014). Autism spectrum disorder as early neurodevelopmental disorder: Evidence from the brain imaging abnormalities in 2–3 years old toddlers. *Journal of Autism and Developmental Disorders*, 44(7), 1633–1640.
- Yang, X., Si, T., Gong, Q., Qiu, L., Jia, Z., Zhou, M., Zhao, Y., Hu, X., Wu, M., & Zhu, H. (2016). Brain gray matter alterations and associated demographic profiles in adults with autism spectrum disorder: A meta-analysis of voxel-based morphometry studies. *Australian and New Zealand Journal of Psychiatry*, 50(8), 741–753.
- Young, K. S., Rennalls, S. J., Leppanen, J., Mataix-Cols, D., Simmons, A., Suda, M., Campbell, I. C., O'Daly, O., & Cardi, V. (2020). Exposure to food in anorexia nervosa and brain correlates of food-related anxiety: Findings from a pilot study. *Journal of Affective Disorders*, 274, 1068–1075, 16.
- Zhang, S., Wang, W., Su, X., Kemp, G. J., Yang, X., Su, J., Tan, Q., Zhao, Y., Sun, H., Yue, Q., & Gong, Q. (2018). Psychoradiological investigations of gray matter alterations in patients with anorexia nervosa. *Translational Psychiatry*, 8(1), 1.
- Zhu, Y., Hu, X., Wang, J., Chen, J., Guo, Q., Li, C., & Enck, P. (2012). Processing of food, body and emotional stimuli in anorexia nervosa: A systematic review and meta-analysis of functional magnetic resonance imaging studies. *European Eating Disorders Review*, 20(6), 439–450.
- Zielinski, B. A., Anderson, J. S., Froehlich, A. L., Prigge, M. B., Nielsen, J. A., Cooperrider, J. R., Cariello, A. N., Fletcher, P. T., Alexander, A. L., Lange, N., Bigler, E. D., & Lainhart, J. E. (2012). scMRI reveals large-scale brain network abnormalities in autism. *PLoS One*, 7(11), e49172–113.
- Zimmermann, K. S., Richardson, R., & Baker, K. D. (2019). Maturation changes in prefrontal and amygdala circuits in adolescence: Implications for understanding fear inhibition during a vulnerable period of development. *Brain Sciences*, 9(3), 65.

## SUPPORTING INFORMATION

Additional supporting information can be found online in the Supporting Information section at the end of this article.

**How to cite this article:** Sader, M., Williams, J. H. G., & Waiter, G. D. (2022). A meta-analytic investigation of grey matter differences in anorexia nervosa and autism spectrum disorder. *European Eating Disorders Review*, 30(5), 560–579. <https://doi.org/10.1002/erv.2915>