

Review Article

Thalidomide Embryopathy: An Enigmatic Challenge

Neil Vargesson

School of Medical Sciences, Institute of Medical Sciences, University of Aberdeen, Foresterhill, Aberdeen AB25 2ZD, UK

Correspondence should be addressed to Neil Vargesson; n.vargesson@abdn.ac.uk

Received 9 July 2013; Accepted 18 August 2013

Academic Editors: J. M. Hurlle and G. Tettamanti

Copyright © 2013 Neil Vargesson. This is an open access article distributed under the Creative Commons Attribution License, which permits unrestricted use, distribution, and reproduction in any medium, provided the original work is properly cited.

Thalidomide remains one of the world's most notorious drugs due to the severe birth defects it induced in children between 1957 and 1962. Yet, to some this drug is a lifesaver, as it now enjoys renaissance in the treatment for a wide range of conditions including leprosy, multiple myeloma, Behcet's disease, and some cancers. However, thalidomide has also been linked to causing a new generation of thalidomide survivors in Brazil, where the drug is used to treat leprosy. Surprisingly how thalidomide causes birth defects and how it acts in the treatment of clinical conditions are still far from clear. In the past decade great strides in our understanding of the actions of the drug, as well as molecular targets, have been made. The purpose of this review is to look at the recent work carried out into understanding how thalidomide causes birth defects, its molecular targets and the challenges that remain to be elucidated. These challenges include identifying clinically relevant but nonteratogenic forms of the drug, and the mechanisms underlying phocomelia and species specificity.

1. Introduction

1.1. History. Thalidomide was produced and released as a nonaddictive, nonbarbiturate sedative in 1957 by Chemie-Grünenthal. Thalidomide was marketed as very safe with no untoward side effects [1] and quickly became something of a wonder drug between 1957 and 1961 in the treatment of a range of conditions, in particular morning sickness. Thalidomide was marketed in 46 countries, under different names (e.g. Distaval in the UK and Australia, Isomin in Japan, Contergan in Germany, and Softenon in Europe) [1–4]. However soon after the drug's release in Europe reports linked thalidomide to causing peripheral neuropathy in adult patients (which prevented its licensing and general release in the USA) as well as being behind the occurrence of a high and sudden increase of rare birth defects [3, 5–8]. The range and type of birth defects seen were unprecedented with the most striking and stereotypic feature being phocomelia, where the handplate remains but the proximal elements are missing or very short. Children also exhibited amelia in some cases (no limb) forelimb anomalies, handplate anomalies, and other damage to ears, eyes, internal organs, genitalia, and the heart [7, 9–20]. The damage caused by thalidomide was not mutually exclusive, with the majority of children

exhibiting damage to multiple organs and tissues [3, 7]. It took until 1961, when reports and concerns from two independent clinicians, Lenz in Germany and McBride in Australia, confirmed that ingestion of thalidomide during pregnancy, to relieve morning sickness, was the cause of the birth defects [3, 4, 7, 11, 12, 21]. Thalidomide was finally withdrawn in November 1961. Thalidomide-damaged children were still born throughout 1962, but the number of children affected dramatically declined following thalidomide withdrawal [7, 22]. In total over 10000 children were born with severe damage worldwide [3, 23].

Thalidomide was not licensed for use in the USA between 1957 and 1961 as Dr Frances Kelsey, a physician working for the US Food and Drug Administration (FDA) had concerns about the drug's safety [5, 24]. Dr. Kelsey was concerned about the peripheral neuropathy side effect that had been experienced and reported in some patients in Europe following thalidomide exposure [3, 5, 25, 26]. Dr. Kelsey undoubtedly prevented an epidemic of thalidomide-induced birth defects in the USA and for her efforts was subsequently given the President's Award for Distinguished Federal Civilian Service by President John F. Kennedy in 1962 [4]. Questions still remain about the testing carried out on Thalidomide before it was marketed in 1957 and whether

the testing was stringent enough as well as whether the disaster was preventable. Following the thalidomide disaster new legislation was introduced around the world that changed the way drugs are tested and their approval for human use, especially for pregnant women. Indeed Dr Frances Kelsey published several papers on improving drug testing and safety, which form the basis of drug testing carried out today [5, 6].

1.2. Thalidomide Today. In 1965 thalidomide was found to be very effective in reducing the lesions associated with leprosy and (ENL), erythema nodosum leprosum, a complication of leprosy involving a chronic skin and nerve infection caused by *Mycobacterium leprae* [27]. This discovery led to thalidomide's actions being studied in detail for clinical purposes. Reports linked the drug to having anti-inflammatory actions and being effective as a clinical treatment for Leprosy, ENL, and other inflammatory disorders. Furthermore studies indicated thalidomide was antiangiogenic and potentially useful for the treatment of cancers [28, 29]. Today thalidomide is licensed around the world (including the USA since 1998) for the treatment of leprosy and multiple myeloma (where it can prolong patients lives by up to 18 months) [30, 31]. Thalidomide and its analogs are also used to treat a broad range of other conditions including in the gastrointestinal system (e.g. Behcet's disease, Crohn's disease), rheumatological system (e.g. lupus, arthritis, and sarcoidosis), and cancers (e.g. renal cell cancer, prostate cancer, and Kaposi's sarcoma) [1, 32, 33]. Recently thalidomide has been shown to be effective in relieving the clinical symptoms of hereditary hemorrhagic telangiectasia (HHT), a bleeding disorder [34] and idiopathic pulmonary fibrosis [35, 36]. Clearly thalidomide has some very beneficial clinical uses. However the dark side of thalidomide still remains. Thalidomide still causes birth defects today particularly in Brazil—where several children have been identified with thalidomide embryopathy in the past few years [37–40].

1.3. Brazil Tragedy. In recent years tragically a new generation of thalidomide survivors have been born and identified in Brazil [37–40]. This is primarily due to a culture of medication sharing, less-stringent methods of prescription, misunderstanding of the drug's labeling, and pregnant women taking the drug while suffering from leprosy. Sadly many children have been identified with thalidomide embryopathy [39, 40]. This Brazilian cohort provides an opportunity to follow these victims from childhood to adulthood using modern diagnostic techniques. Such studies could help determine the precise range and type of damage at birth as well as late onset damage. So far, the Brazilian thalidomide survivors appear to exhibit a similar spectrum of damage as seen in the 1957–61 disaster [39, 40].

2. Thalidomide Embryopathy (or the Thalidomide Syndrome)

Between 1957 and 1961 thalidomide caused severe birth defects in at least 10000 children [1, 3]. Although any tissue of the forming body could be affected by thalidomide some

hallmark features associated with the drug were identified including damage to limbs, eyes, ears, genitalia, and internal organs including kidney, heart, and gastrointestinal tract. Also associated are vertebral column problems and facial palsy [1, 3, 7, 9, 11–15, 18, 20, 41, 42]. In addition another common feature was the appearance of a transient haemangioma on the forehead, which usually disappeared within the first 12–24 months of life [7]. Due to the wide range of conditions this drug caused the damage is usually referred to collectively as thalidomide embryopathy or thalidomide syndrome [7, 14, 15]. Infant mortality in babies born with thalidomide embryopathy is estimated to be as high as 40%, quite likely due to the serious internal malformations such as heart and kidney defects [3, 7]. Furthermore many babies with these serious internal malformations would have been miscarried or died *in utero* or soon after birth. Thus, the true number of babies affected by thalidomide will never be known.

2.1. Thalidomide Acts in a Time-Sensitive Window of Embryonic Development. Thalidomide causes damage to the embryo in a short time window of development (also referred to as the “critical period”) between 20 and 36 days after fertilisation, or 34 to 50 days after the last menstrual period [7, 11, 25]. Exposure to thalidomide from 36 days after fertilisation has no apparent outward morphological effect upon the embryo/fetus [7, 14]. In contrast, thalidomide exposure before the time-sensitive window of development can induce miscarriage in humans and rats [9, 43]. Incredibly, reports indicate just one 50 mg tablet of thalidomide during the time-sensitive window is sufficient to cause birth defects in 50% of pregnancies, underlining the high teratogenic potency of thalidomide [7, 14, 15, 25]. Some reports go further and suggest it would be surprising if any pregnancy went unharmed following thalidomide exposure during the time sensitive window [7]. The time-sensitive window was determined following interviews with mothers of thalidomide-affected children and their doctors. From these interviews the dates of intake and the amount of drug exposure were calculated and an accurate correlation could be made to the period of exposure and relationship to anomalies in order to determine the timing of the damage [3, 11, 25]. The outward morphological birth defects seen in thalidomide embryopathy are caused and correlate with exposure within this time period. Exposure to thalidomide in the first few days of the sensitive period (days 20–24) affected the ears and eyes, followed by the upper limb (day 24–31) and then the lower limb (days 27–33), respectively [11, 25]. Effects upon the nerves, resulting in facial palsies, hearing loss and autism and epilepsy could be induced from the start of the time sensitive window, presumably as the brain's neural wiring is undergoing great changes at this time. The consequence of such nerve damage, however, may not be diagnosed until much later after birth [11, 25, 42]. Thalidomide exposure in late fetal rat's indicates that brain damage in areas related to autism can be a late event [44].

The time-sensitive window coincides with a period of rapid embryonic development (from 4 weeks onwards) with lots of cell movements, organogenesis, and many signalling

pathways active. Embryogenesis typically lasts until around weeks 10-11 after conception. Thus, Thalidomide use to relieve the symptoms of morning sickness (which can occur from week 4 onwards) coincides with the major developmental events in the embryo underpinning the thalidomide tragedy [1, 3].

Exposure to thalidomide after the time-sensitive window was thought to have no effect upon the embryo. Recent work has suggested late exposure of rat fetuses to thalidomide (after the documented time-sensitive window of action in the late fetal stages) affects angiogenesis in the brain and causes malformations of the brain in areas linked to epilepsy and autism, with no obvious limb or other outward morphological damage [44]. Epidemiology studies in Sweden have shown that thalidomide survivors have an increased incidence of autism when compared to the average population [42, 45]. Together, this work suggests there is unlikely to be a safe time point in pregnancy for exposure to thalidomide. Exposure in the time-sensitive window results in a range of outward morphological damage, with the severity and complexity depending on timing of exposure. Exposure after the time-sensitive window could affect growth and maturation of internal organs/tissues, particularly the brain.

2.2. Limb Defects. Phocomelia is the most striking limb deformity caused by thalidomide and remains the stereotypical image of thalidomide embryopathy. Phocomelia is a severe shortening of the limbs, where distal elements (handplate) remains but proximal elements (long bones) are reduced or missing [7, 14, 15, 46, 47]. Phocomelia itself can range in severity. The most severe form is where long bones are missing with just a flipper-like structure consisting primarily of a handplate (though digit number can vary between affected individuals) articulating directly with the body. Less severe forms show, for example, a shortening of the long bones [7, 14, 39, 46]. The majority of thalidomide survivors exhibit some form of limb deformity for example, phocomelia to radial dysplasia to triphalangeal thumb [1, 7, 20, 39]. Limb deformities are usually reduction defects and most often symmetrical [7, 9, 14, 48]. Indeed severe, symmetrical limb defects remain one of the classical hallmarks for diagnosis of thalidomide embryopathy. The range and type of limb deformities following thalidomide exposure are described in the literature (originating from the 1960s) as exhibiting a characteristic pattern. The thumb is the first structure to be affected followed by the radius, humerus, and lastly the ulna [7, 9, 14, 15, 49]. These descriptions were based on observations of babies and children with severe forms of thalidomide embryopathy, usually exhibiting bilateral limb damage [7, 15, 17].

The lower limb can also exhibit limb deformities. However abnormalities of the lower limbs are seen less commonly than those of the upper limbs, with lower limb deformities on their own being very rare. The reasons for this upper limb/lower limb sensitivity difference to thalidomide remains unclear [14, 16, 48]. The femur is the bone most often affected in the lower limb, and like the ulna, in the upper limb, the fibula is usually the final bone to remain normal [7].

Embryologically, the radius/tibia (preaxial) and ulna/fibula (postaxial) form in the developing limbs after the humerus/femur has begun to form. The digits of the hand/footplate are the last structures to form. Initially the structures form as cartilage condensations before ossifying into bone [50–52]. This sequence of limb development offers some explanation as to why proximal structures are shortened or missing but distal structures are present in some thalidomide survivors; that is, early exposure causes loss of proximal elements. However how any distal structures then form or remain is unclear (also see discussion on chondrogenesis and origins of phocomelia, later in this review).

Why the radius is more sensitive to thalidomide-damage than the ulna is unclear. The radius is smaller and thinner than the ulna and so perhaps easier to damage. However, variations in deficiencies longitudinally have been suggested to be related to the timing and duration of a teratogenic insult during early limb development [53, 54]. It has also been reported that teratogenic insults could induce ulnar deficiencies earlier in gestation than radial deficiencies [53].

Unilateral limb damage is not considered to be part of the classical thalidomide embryopathy phenotype. However there are reports in the literature mentioning cases of thalidomide survivors with unilateral limb damage [7, 11, 16, 17, 20, 55]. Unilateral defects, in general, are very rare and how they come about remains a mystery.

2.3. Shoulder and Hip Joints. Thalidomide survivors also exhibit damage to the shoulder and hip joints where the limbs articulate with the body and are often weaker than normal. The acromioclavicular joint of the shoulder is more prominent and sharpened in appearance, when the shoulder is deformed [14]. The hip joint may be hypoplastic or completely absent, as is true for the pubic bone [14]. Damage to the shoulder and hip joints is a characteristic of thalidomide embryopathy and in some cases has helped physicians to differentiate thalidomide deformities from sporadic or genetic limb defects. Adult thalidomide survivors have commented on ongoing joint problems, pain and rotation difficulties and early-onset osteoarthritis [56, 57].

2.4. Eye and Ear Defects. Damage to the eyes and ears (internal and external) is also seen in thalidomide survivors. The eyes and ears form from week 4/5 until around week 8/9, around the same time the limbs are rapidly growing. Thalidomide can cause small eyes (microphthalmia) anophthalmos (absence of the eyeball) and poor vision. Eye defects also include aberrant lacrimation (tear formation), coloboma and strabismus [7, 14, 17, 20, 25, 45, 58]. Ocular defects can occur unilaterally although there may still be poor vision in the unaffected eye [17]. Thalidomide may also cause abnormalities in eye movement and usually occur in conjunction with ear defects and weakness of the facial muscles [7].

Ear defects are usually symmetrical and range from complete absence of the outer ear or pinna (anotia) to part of the outer ear still remaining (microtia) [7, 59, 60]. Anotia is also linked to abnormalities of the external auditory meatus and

such children affected are deaf [60]. Thalidomide-induced ear defects have also been associated with cranial nerve palsies, resulting in facial palsies [13, 14, 25].

2.5. Facial Damage. Another common feature seen in thalidomide survivors, again used as a diagnostic hallmark, is the presence of an enlarged naevus at birth (also known as a “storkmark”). The naevus is in the centre of the forehead extending down over the nose and upper lip. This is a capillary haemangioma and is temporary, usually no longer visible within 2-3 years of birth [7, 14, 15]. Facial palsy and facial asymmetry have also been associated with thalidomide embryopathy [7, 14, 15, 20, 25] and are thought to be due to weakened facial muscles and facial nerve damage [7, 25]. In addition a range of other effects on facial structures have been seen in thalidomide survivors including irregular teeth numbers/spacing, small jaw, cleft palate and cleft lip, and small noses [7, 14].

2.6. Vertebral Column. Thalidomide survivors can exhibit spinal problems, including irregular vertebral spacing. Fusion of vertebrae is also seen in the lower spinal column and progressive kyphosis which can often require surgical intervention later in life [7, 14]. Thalidomide survivors have also been reported to exhibit shorter stature than average with the shortness attributable to short leg bones being independent of vertebral defects [7, 14, 61]. How these spinal defects occur following thalidomide exposure is unclear.

2.7. Internal Organ Defects. All of the internal organs can be affected by thalidomide exposure *in utero*. Common damage seen includes malformations of the heart, kidneys, genitals, and bowel [7]. The precise incidence of such deformities is unknown as such defects cannot be seen outwardly and some problems do not always present until later in life. Defects of the heart were thought to be the cause for many of the intrauterine and postnatal deaths. Many thalidomide survivors have heart problems as well as pulmonary stenosis and patent ductus arteriosus [7, 59].

The urinary tract and kidneys are affected in many thalidomide survivors, with horseshoe, hypoplastic, and rotated and ectopic malformations of the kidney seen [7, 14, 15, 17]. Many children also suffered from genital defects, both internal and external. Absence of the testes, testicular abnormalities, and hypospadias were seen in males, whilst in females malformations of the uterus and reproductive tract defects were observed [7, 16, 17, 62]. Thalidomide survivors exhibited problems in the intestines including anorectal stenosis, intestinal atresia, pyloric stenosis, and inguinal hernia [7, 9, 14–17].

2.8. Nerve and CNS Defects. Children with thalidomide embryopathy did not appear at the time to have impaired learning disabilities [63, 64]. There is evidence that some thalidomide-damaged children have facial palsies, cranial nerve conduction problems, and an increased incidence of autism and epilepsy in later life [7, 25, 42]. It has been proposed that thalidomide could affect forming nerve

pathways during, and outside, the time sensitive window [42, 44, 45] possibly by preventing angiogenesis in the brain [44] resulting in cell death and loss of tissue and autism.

2.9. Variability of Thalidomide-Induced Damage between Individuals. An outstanding question, and perhaps ongoing challenge, is to understand the variability of thalidomide-induced damage between individuals [1, 7]. Some reports indicate thalidomide exposure *in utero* could result in a 50% risk of a birth defect [7, 14, 15]. Given the potency of the drug how could any pregnancy be unharmed? Why are some pregnancies apparently unharmed? Aside from drug exposure *in utero* outside the time-sensitive window of action, we know that individuals react differently to drugs and we know individuals have different metabolic rates. Birth defects can be multifactorial in origin resulting from combined genetic and environmental influences [65]. Thus, these influences (as well as time of exposure) could explain why some pregnant women are affected by the drug and others are not, and also explain differences in the severity of the damage.

2.10. Thalidomide Embryopathy Can, Sometimes, Be Difficult to Diagnose. Reports have indicated that some thalidomide survivors may have been misdiagnosed and in fact suffer from mutations in the SALL4 gene or in the TBX5 gene [66–68]. SALL4 and TBX5 are both expressed in limbs. Mutation in SALL4 causes Okhiro syndrome, characterized by limb reduction deformities. Mutations in TBX5 causes Holt-Oram syndrome, where heart and limb reduction deficiencies are apparent. Both Okhiro syndrome and Holt-Oram syndrome can be difficult to differentiate from thalidomide syndrome as they can look similar.

In addition another genetic condition that can be confused with thalidomide embryopathy is Roberts syndrome. Roberts syndrome is also called pseudothalidomide syndrome, as it shares striking resemblance to Thalidomide embryopathy in that the main feature is tetraphocomelia [69]. Roberts syndrome patients also suffer from facial and internal organ damage [70]. Roberts syndrome is caused by a mutation in the ESCO2 gene (Establishment of Sister Chromatid Cohesion 2) [71, 72], involved in proper segregation of chromatids in cell division. This gene has since been found to be important in control of cell proliferation, cell death and DNA repair [73, 74]. The advent of genetic screening now allows better diagnosis of such conditions.

Thalidomide can phenocopy these genetic defects and further highlights the difficulty in sometimes differentiating thalidomide embryopathy from other disorders. This also underlines the difficulties in pinpointing precise diagnostic parameters of thalidomide embryopathy, given the range of damage and variability between individuals. Furthermore, whether these genes may be involved in some of the downstream, tissue specific effects of the drug is unclear (see later section on molecular targets).

2.11. Summary. The damage caused by thalidomide is striking and widespread. The criteria describe above varied between

individuals, the most severely affected children exhibited limb malformations, facial, genital and internal organ problems. These criteria are used to help diagnose thalidomide embryopathy. The criteria were determined through studying the most severely affected thalidomide babies/children, usually those with bilateral limb damage [7]. Damage that may only have observable effects in later life, such as joint damage or reduced organ/tissue function could not be properly determined. Thus, some damage may not have been apparent at that young age, and may not have been associated as part of the condition as patients got older. Furthermore, there are records of children with confirmed thalidomide exposure *in utero* with no apparent outward morphological damage [20]. Whether such children have internal organ damage/function issues is unknown. The precise range of damage may never be known. However, the Brazilian thalidomide survivors, many of whom being children, offer the possibility of studying the damage caused, its progression and late onset problems.

Today, we are aware of left-right asymmetry differences in early embryonic formation, asymmetric differences internally, and genomic variation between individuals which could influence susceptibility to a drug's influence [65]. How thalidomide influences these processes remains unclear but could shed further light on the molecular and tissue targets of the drug. Understanding thalidomide and its targets remains a priority due to its widespread use in clinical treatments today.

3. Thalidomide Has Side Effects in Adults

Thalidomide is not only toxic to the forming embryo. It has been known since the original release of thalidomide that long term use can cause peripheral neuropathy in adults [5, 75–77]. Peripheral neuropathy is a condition where nerves are damaged resulting in pain and hypersensitivity, typically in the extremities [78]. How the drug induces this condition is unclear; however patients are advised to stop taking thalidomide if symptoms begin. In patients using thalidomide to treat leprosy and multiple myeloma, many suffer from peripheral neuropathy [76, 79].

In addition thalidomide use causes constipation, dizziness, drowsiness, and skin rashes in some patients. Recent regulatory advice warns that thalidomide can also cause blood clots in veins and arteries and has recently also been linked to inducing secondary malignancies (<http://www.thalomid.com/>; <http://www.fda.gov/>; <http://www.mhra.gov.uk/Safetyinformation/DrugSafetyUpdate/CON123111>; <http://www.mhra.gov.uk/Safetyinformation/DrugSafetyUpdate/CON282739>).

4. Lenalidomide and Pomalidomide: New Thalidomide Analogs

New analogs of thalidomide have been developed that are purported to be safer and more clinically effective than thalidomide in the treatment of inflammatory disorders. These analogs, lenalidomide and pomalidomide, are used to effectively treat multiple myeloma [80]. Pomalidomide

appears to be more effective in treating patients in which lenalidomide and thalidomide have lost effectiveness [81, 82] (Figure 1).

However, lenalidomide use has been linked to causing peripheral neuropathy in patients taking lenalidomide for multiple myeloma treatment [83, 84]. In addition lenalidomide, but not pomalidomide, is teratogenic in chick and zebrafish embryos [85]. Furthermore, both lenalidomide and pomalidomide are associated with causing teratogenesis in some mammalian species [86] (also see FDA website: http://www.accessdata.fda.gov/drugsatfda_docs/label/2013/204026lbl.pdf). The basis for these species-specific differences in action is far from understood (see Species Specificity section of this review for further discussion).

Clearly, these compounds, including thalidomide, remain a risk to the unborn child and are only administered under a strict program which is specifically designed to prevent thalidomide embryopathy. For example, the System for Thalidomide Education and Prescribing Safety (STEPS) is a program that educates clinicians and patients and carries out regular contraceptive counseling and pregnancy testing [87–89]. However, presently the other side effects (e.g. peripheral neuropathy) are sadly part of the risk-benefit decision associated with the drug's health benefits. It remains a primary goal to ascertain if all such side effects can be prevented or minimized. Whether new or alternative forms of the drug can be made retaining the clinically beneficial aspects and without the side effect aspects is an ongoing challenge.

5. Biochemistry of Thalidomide

Thalidomide is a derivative of glutamic acid, a nonessential amino acid with important functions in the brain and during muscle development. Thalidomide exists as an enantiomer and can switch between its two chiral states in body fluids and water [29] (Figure 1). It has long been assumed that one form is the teratogenic causing agent and the other is the sedative agent. However, the fact they can interchange indicates just the safe form cannot be given clinically [29, 90, 91]. Thalidomide is metabolically broken down in the liver by cytochrome P450 (CYP2C19) enzymes and can also break down hydrolytically in body fluids. Thalidomide has a half-life of 6–12 hrs [29]. Furthermore there are species differences in efficiency of breakdown of drug into byproducts; for example, the rabbit is more effective at breaking down thalidomide than the rat [92, 93]. This could help explain the species differences in action of this drug (see later).

5.1. Inflammation. Thalidomide has been shown to inhibit TNF α transcription directly through enhanced TNF α mRNA degradation [94] and COX2 inhibition [95] in monocytes and macrophage cells. TNF α regulates and controls the inflammatory response through inducing cytokines, such as interleukins (e.g., IL-1 and IL-6), in response to injury or stimuli. Several autoimmune diseases arise from the overproduction of unnecessary cytokines in healthy tissue, leading to potentially debilitating conditions, such as erythema nodosum leprosum (ENL), multiple myeloma (MM),

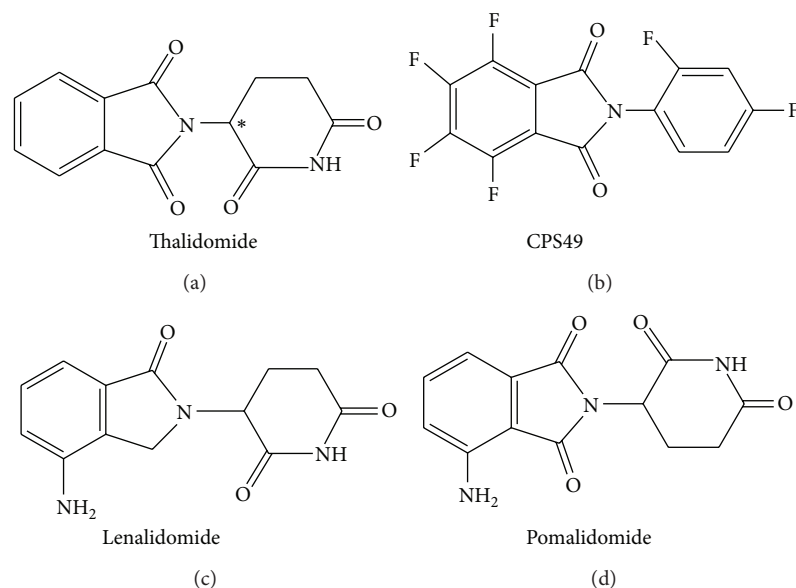


FIGURE 1: Structures of thalidomide and its structural analogs. Thalidomide (a) is enantiomeric and can exist in two chiral states (asterisk denotes chiral centre). CPS49 (b) is a structural analog based on the antiangiogenic breakdown product of the thalidomide molecule and is fluorinated to enhance bioactivity and stability [1, 29, 54]. Lenalidomide (c) and pomalidomide (d) are based on the thalidomide structure and used to treat multiple myeloma.

and Crohn's disease [96, 97]. The inhibition of $\text{TNF-}\alpha$ by thalidomide makes this drug excellent in the treatment of these autoinflammatory diseases.

5.2. Angiogenesis. Thalidomide was first demonstrated to be antiangiogenic in 1994, through destroying angiogenic vascularization in rat cornea induced by fibroblast growth factor (FGF) protein [28]. This finding led to the suggestion that thalidomide may cause teratogenic damage by affecting blood vessels. Indeed this discovery has made thalidomide a candidate for treatment of early-onset cancers, to prevent early cancerous growth/tumors acquiring a vasculature to grow [29, 90, 91]. Thalidomide is also used to treat multiple myeloma, which is thought to be due to excessive vascularization of bone marrow tissue and/or due to an overactive inflammatory response [98], and also treat hereditary hemorrhagic telangiectasia (HHT) [34].

Use of CPS49, an antiangiogenic analog of thalidomide, demonstrated that thalidomide's antiangiogenic action causes its teratogenic actions in a time-sensitive manner [54].

6. Angiogenesis and Mechanism of Thalidomide-Induced Teratogenesis

6.1. Role of Blood Vessels in Embryogenesis. Blood vessels are essential for normal embryonic formation. Blood vessels supply oxygen and nutrients to growing tissues and remove unwanted waste products. Blood vessels form by two main processes in the embryo: vasculogenesis and angiogenesis (Figure 2). Vasculogenesis is where the first, primitive blood vessels form. Endothelial cells migrate toward each other and coalesce to form vascular tubes. Angiogenesis is where these

primitive vascular tubes are built upon and elaborated to form the complex networks of vessels throughout all tissues of the embryo. Endothelial cells proliferate and migrate to avascular areas in response to signals such as hypoxia or vascular endothelial growth factor. Endothelial cells then quiesce and the vascular tube recruits vascular smooth muscle cells which stabilise and strengthen the vessel. In order to undergo later angiogenesis to further elaborate the network or simply refine the network, the smooth muscle coating is lost to allow endothelial cells to migrate and form new vascular tubes (Figure 2) [99, 100]. As embryonic development proceeds blood vessels undergo constant rounds of angiogenesis and stabilisation to accommodate the rapid tissue changes and growth.

Loss of, or inhibition of, blood vessels during embryogenesis can result in death or severe embryonic development consequences [99–102]. For example, loss-of-function experiments of genes involved in vascular formation (e.g., VEGF and Notch) in mouse embryos cause lethality as the vasculature fails to form [99, 100, 103–105]; in zebrafish, Notch signalling pathway mutants display vascular disruption in the forming somites and spine of the embryo resulting in severe spinal curving of the embryo [106, 107]. Blood vessels are important for normal embryonic development, and their loss, unsurprisingly, results in death or birth defect [1, 52, 100, 102].

6.2. Blood Vessels Are Targeted by Thalidomide in Embryonic Development. Thalidomide has antiangiogenic actions which has been proposed to play a role in thalidomide teratogenesis [1, 2, 28, 108–110]. Thalidomide can break down into many byproducts. Many stable, structural analogs of thalidomide and its breakdown products have been synthesised and can

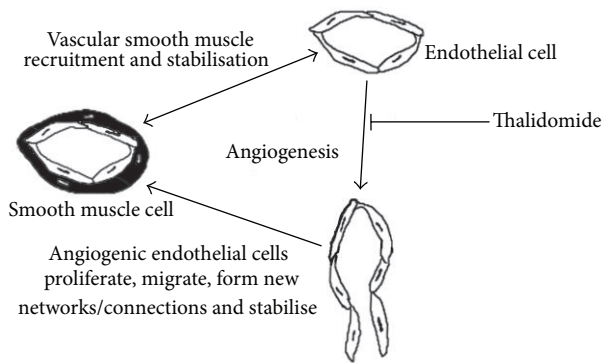


FIGURE 2: Angiogenesis and the action of thalidomide upon angiogenesis. Primitive vessels form through vasculogenesis where endothelial cells coalesce to form primitive tubes through which blood cells pass through. Angiogenesis is the process which elaborates upon these early and newly formed vessels to form vascular networks throughout tissues and the embryo. Angiogenesis is essential for formation of the embryo and continues into adulthood, for example, wound healing. As vessels form they recruit vascular smooth muscle which stabilises the vessel into a mature and quiescent state. Angiogenesis is induced by signals such as hypoxia inducible factor-1 (HIF1), vascular endothelial growth factor (VEGF), and transforming growth factor- β (TGF β). Mature vessels will shed their vascular smooth muscle coats and endothelial cells will proliferate and migrate to the source of the signals and form new vessels. Thalidomide targets the immature, unstable, newly formed vessels preventing proliferation and migration of the endothelial cells. In rapidly growing tissues, e.g. the forming limb, vessel loss will be devastating, as cell death will be induced and signalling pathways will be disrupted.

be screened to determine their function, shedding light on which aspect of thalidomide action, antiangiogenesis, or anti-inflammation results in teratogenesis [29, 54, 109–111].

CPS49 is one such stable antiangiogenic analog of Thalidomide (Figure 1). CPS49 is a tetrafluorinated analog based on the antiangiogenic breakdown product of thalidomide, 5'-OH-thalidomide [1, 29]. Fluorination confers stability and increased biological activity [1, 29, 110, 111].

Following CPS49 treatment in chick embryos, as limbs are just forming (E2.5), blood vessels were destroyed within 1 hr of exposure in the embryo and several hours before any changes in limb signalling gene expression, and cell death was observed (Figure 3). Reduction in limb area was seen within 6 hrs. Truncated limbs were clearly observable by 24 hrs where increased cell death was observed and loss of FGF and Sonic hedgehog (Shh) signalling was seen. FGF and Shh are key signalling molecules in the developing limb controlling patterning and outgrowth (Figure 3). Thalidomide has also been reported to cause loss of FGF and Shh signaling in chick and rabbit embryonic limbs and in zebrafish embryos [112–114]. In CPS49 treated embryos resulting limbs were phocomelia-like 7 days after just a single exposure (Figure 3). Even more interesting is that CPS49 acts in a time-sensitive window, just like Thalidomide, where early exposure resulted

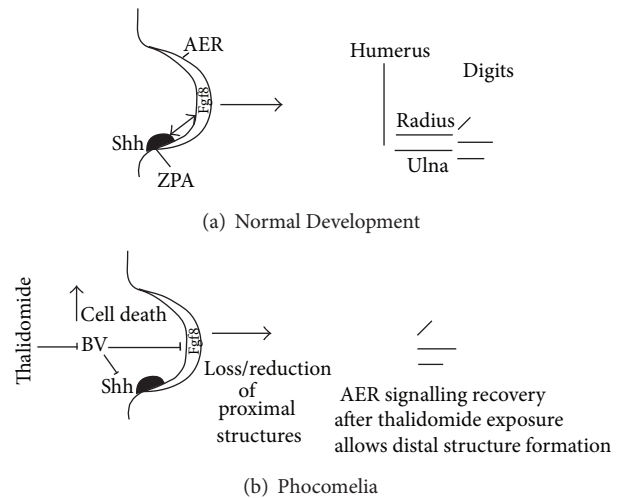


FIGURE 3: Limb development and thalidomide-induced phocomelia. (a) Normal limb development. The limb grows out from the embryonic flank under the control of several signalling regions, the Zone of Polarising Activity (ZPA) and the Apical Ectodermal Ridge (AER). These signalling regions release signalling molecules Shh and Fgf8, respectively, which signal in a feedback loop and control limb outgrowth and patterning. Ultimately other genes are activated including Hox genes, which are involved in patterning the fine detail of the cartilage elements [51, 52]. (b) Model of thalidomide-induced phocomelia. Thalidomide inhibits blood vessel formation and migration, resulting in cell death and reduced signalling between the ZPA and AER. Once thalidomide exposure has ceased or limb has recovered, AER/ZPA signalling could be reestablished and remaining cells distalised to produce a phocomelic limb. If thalidomide exposure was long term, AER/ZPA signalling may be completely abolished, resulting in Amelia.

in severely truncated limbs and later exposure caused less severe damage, for example, loss of a digit or digit tips only. Similarly, in zebrafish embryos blood vessels are stunted and lost rapidly following CPS49 treatment. Zebrafish embryos offer the advantage of being able to visualise vessel formation and migration “live and *in vivo*” and effects of drug upon vessel formation and migration. CPS49 was shown to prevent endothelial cells from proliferating and migrating to form new tubes [54]. The action of CPS49 on the endothelial cell is through preventing cytoskeletal changes and inhibition of filopodial tip cell formation and migration [54]. It was further demonstrated, using *in vitro* rat and mouse aortic ring culture assays, that blood vessels possessing smooth muscle coats are protected from the action of the drug, but those without smooth muscle are destroyed. This indicates that newly formed and forming blood vessels are susceptible to thalidomide. Established, quiescent vessels are unharmed. In the chick embryo the developing limb vasculature does not possess smooth muscle until quite late in limb development [54, 115]. This observation correlates with the range of limb defects seen depending on the timing of exposure. Severe defects are seen after early exposure, but by the time smooth muscle has appeared on the limb vasculature, defects are restricted to digits [54]. In contrast to the limb, at the time of exposure (E2.5) microvessels in the brain and vessels in

the neck and body of the embryo possess smooth muscle coats intimating that these vessels are quiescent and protected at this time. When the drug was applied to very young embryos (E1.5), when most tissues are being vascularised and organogenesis is occurring, embryos died [54].

Several nonantiangiogenic analogs and hydrolysis products tested using the same assays were found not to be teratogenic or harmful to embryos [54]. This work indicated that the antiangiogenic action of the drug causes a wide range of limb defects in a time-dependent manner.

A study using a different fluorinated analog of the thalidomide molecule (fluorothalidomide) in mouse and rabbit embryo cultures gave a range of damage that differed from that exhibited following thalidomide exposure (e.g. no obvious or apparent limb defects) and also broke down very rapidly [116]. The work suggests fluorination of compounds changes their activity [116]. Embryo cultures ideally last around 2 days and as such it can be difficult to determine the precise range and type of damage caused by drugs in such embryos (certainly whether limbs exhibit limb reduction phenotypes or missing cartilage patterns). The fluorothalidomide compound appears unstable and could have broken down before it could cause observable damage to limbs. Whether there were any effects on limb signalling pathways (e.g. FGF, Shh, etc.), changes in cell death, or changes in blood vessel patterning in the early limbs and embryos is unreported. CPS49 is fluorinated and based on the structure of the active antiangiogenic breakdown product of thalidomide and induces a range of damage and molecular changes in embryonic chick limbs and *in vitro* assays, which is consistent with reports from other groups and work using thalidomide [112–114, 117–120].

Several other studies have also demonstrated that blood vessels are targeted and destroyed by thalidomide [28, 44, 108, 119, 121]. These include rat and rabbit corneal assays where blood vessels induced in response to an FGF soaked bead are destroyed following thalidomide application [28, 108]. In rat fetuses exposed to thalidomide late in gestation, blood vessels are disrupted which results in brain changes in areas relating to autism [44]. In chick embryos, nitric oxide, a molecule required for endothelial cell function, and that appears to be protective of blood vessels is inhibited by thalidomide causing vessel loss. Overexpression of nitric oxide rescues and/or prevents thalidomide-induced damage [119, 121, 122]. In zebrafish embryos thalidomide causes blood vessel defects [54, 123] through VEGF receptor depletion [123]. Thalidomide has also been shown to stabilise hereditary hemorrhagic telangiectasia (HHT) in adult patients where “leaky” vessels stabilise through recruitment of smooth muscle and inhibition of angiogenesis [34].

Furthermore, it is known that other antiangiogenic drugs are teratogenic, for example, sodium valproate [102, 124]. Moreover, loss of blood vessels in early development is usually lethal or causes serious deformity/damage [1, 52, 54, 100, 102, 115].

Many important molecules involved in embryonic vascular development have been reported to exhibit changed expression patterns following thalidomide exposure, for example, actin and tubulin, integrins, vascular endothelial

growth factor, PDGF β , nitric oxide, ceramide, angiopoietins, and reactive oxygen species [28, 34, 114, 121–123, 125–127].

Altogether there is a large body of evidence indicating a role for blood vessel damage leading to thalidomide embryopathy (also see later Nitric Oxide sections).

6.3. Other Mechanisms of Thalidomide-Induced Teratogenesis. Many models, theories, and hypotheses have previously been presented to try to explain thalidomide-induced embryopathy since the 1957–61 disaster. More than 30 models/theories have been described and include actions on nerves, chondrogenesis, cell death, and DNA. Many signaling molecules have been linked to causing thalidomide embryopathy, including FGF's and IGFs [1, 2, 8, 128, 129]. The majority of these models do not appear to be able to account for all the damage caused in the embryo by the drug nor the time sensitive nature of the drug, and the majority focus primarily on the limb damage. Some of the popular models are described further below. However these models do not need to be mutually exclusive and if put together to produce a framework, in my opinion, can explain the primary and secondary consequences of thalidomide embryopathy (see Figure 4).

6.3.1. Nerve Toxicity. McCredie and McBride (1973) [130, 131] proposed that thalidomide could affect neural crest migration and nerve innervation of tissues resulting in limb outgrowth and other tissue formation failure. However, studies looking at nerve functions in the developing chick and mouse limb indicate that following a loss of nerves, limbs form a normal pattern, although limbs and limb cartilage elements can be shorter in length [132–136]. Furthermore limbs are not innervated until relatively late in limb development, well after limb initiation and outgrowth [134, 137]. How embryonic nerve damage can explain the range of damage and the time sensitive nature of the drug is unclear. It is more likely that nerve damage is secondary to the initial insult of tissue loss through loss of vessels, causing misinnervation and exacerbating the damage.

6.3.2. Cell Death and Reactive Oxygen Species (ROS) Induction. Thalidomide induces formation of reactive oxygen species (ROS) and also cell death in limb tissue [114, 118, 125, 138, 139] and could explain the loss of skeletal elements in the limb as well as other damage to tissues in the body. Induction of oxidative stress in embryonic tissue is required to cause thalidomide embryopathy through cell death induction [114, 118, 125, 138, 140]. ROS induction is linked to causing teratogenesis by other drugs, for example, ethanol and phenytoin [65, 140]. However how thalidomide induces the cell death and ROS in specific tissues and in a time sensitive manner is unclear. Interestingly, cell death induction has also been observed in the forming limb following application of CPS49, an antiangiogenic analog of thalidomide, suggesting the inhibition of blood vessels could be a trigger or involved in induction of ROS and cell death [1, 54].

6.3.3. Chondrogenesis. Chondrogenesis is the process by which the cartilage condensations of the skeletal elements

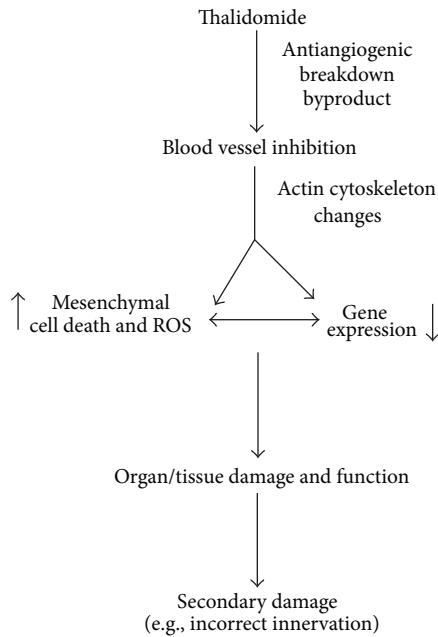


FIGURE 4: Framework of thalidomide teratogenicity. Thalidomide is broken down into active byproducts. The antiangiogenic byproduct inhibits new blood vessel formation in forming tissues and organs (but not mature, vascular smooth muscle coated vessels). The endothelial cells are prevented from proliferating and migrating due to actin cytoskeleton changes. Cell death and localised reactive oxygen species (ROS) are induced and gene signalling pathways are affected resulting in further cell death. In rapidly forming tissues and organs, such as a limb, this is devastating causing tissue loss, for example, of chondrogenic precursor cells, and deformity. The damaged and malformed tissues would then fail to recruit or result in failed secondary cell population migrations, such as nerves and muscles. Such migrating cell types would be mispositioned resulting in a worsening of the defect. The framework could also be applied to tissues and organs that have formed and been patterned before thalidomide exposure. In this case new vessel formation would be inhibited and localised cell death/gene changes would occur as the tissue tries to mature and grow resulting in reduced size and/or reduced physiological function.

form from mesenchyme, and which later differentiate into bone. Thalidomide and its antiangiogenic analog CPS49 induce increased cell death in the early developing limb, when proximal limb element precursors are likely forming, causing limb element reduction or loss [54, 114].

It will be interesting to determine if other chondrogenic condensations in the embryo are similarly affected by thalidomide, for example, the vertebral column.

Phocomelia. The stereotypic limb anomaly associated with thalidomide embryopathy is phocomelia, where proximal limb elements are missing or reduced, but distal elements remain. How does phocomelia come about? Phocomelia can be induced experimentally by X-irradiating the early chick limb bud, resulting in loss of proximal skeletal elements [141, 142], and also through physical removal of proximal and medial limb mesenchyme [143–145]. Reduction of FGF

signaling in the forming mouse limb can also cause phocomelia through loss of proximal elements by increased cell death [146]. We have previously proposed that phocomelia could arise, following thalidomide exposure in early limb development, by loss of blood vessels, inducing cell death and loss of or reduction of distal limb signalling, which recovers to distalise remaining tissues (Figure 3) [1, 54]. We know thalidomide and CPS49 induce increased cell death followed by loss of FGF signaling from the apical ridge in treated limbs soon after drug exposure [54, 112–114]. Could apical ridge signaling recover to signal to and distalise the remaining mesenchymal cells? In chick limbs where proximal and medial tissues have been experimentally removed to induce phocomelia, an upregulation of FGF signaling was observed 24 hrs after tissue removal [145]. In thalidomide exposed rabbit embryos, FGF signalling was reduced in limbs buds, but recovered a few days later, and phocomelic limbs can form [112]. This suggests some distal limb signalling recovery could be a key to understanding thalidomide-induced phocomelia. Alternatively, or in addition, following thalidomide exposure could the early loss of blood vessels and subsequent induced cell death interfere with or prevent cartilage condensation/ossification resulting in shortened/missing elements? And/Or could other distally expressed genes be activated prematurely at the expense of more proximal genes?

6.3.4. DNA Interaction and Mutagenesis. Based on the structure of thalidomide, it has been suggested that thalidomide could intercalate into and/or interfere with DNA function, for example, gene activation [8, 128, 129, 147, 148]. Thalidomide has also been proposed to be able to form dimers which could interact transiently with DNA [147]. It remains unclear how such intercalation/interference events would account for the range and severity of damage induced by thalidomide.

Thalidomide is not mutagenic nor are defects hereditary [66–68, 149, 150]. Reports suggesting thalidomide may be a mutagen followed the birth of a child exhibiting thalidomide-like damage to a thalidomide-damaged parent caused obvious concern [151]. However several detailed and controlled studies have concluded that thalidomide has no mutagenic activity [66, 149, 150]. As discussed earlier, thalidomide can phenocopy some human syndromes, for example, Holt-Oram syndrome, and it can be difficult to differentiate between these conditions, without genetic testing [67, 68]. Furthermore, an epidemiological study in Sweden followed offspring from thalidomide survivors and found no evidence of transmission of thalidomide-damage in the offspring [150].

7. Molecular Targets of Thalidomide

7.1. Cereblon. Cereblon is a candidate gene for mental retardation and has been identified as a binding target of thalidomide leading to limb teratogenesis [113]. Cereblon has also been demonstrated to be required by thalidomide, lenalidomide, and pomalidomide to exert their anti-inflammatory actions [152–154]. Cereblon clearly has multiple important functions in the embryo and body involved in the inflammatory response, mental abilities, teratogenesis, and also

metabolism [155], but its full role in development remains to be characterised.

Cereblon is part of a ubiquitination complex involved in regulating the removal of proteins in the cell and tissues of the embryo/body. Thalidomide is proposed to bind to Cereblon in the forming limb which then causes a misregulation of signalling in the cells and limb bud due to the loss of ubiquitination activity and which results in thalidomide induced limb defects [113]. Overexpression in chick limbs and zebrafish embryos of a mutant form of Cereblon that cannot bind thalidomide rescues the teratogenic effects of the drug [113]. Several studies in chick, rabbit, and zebrafish fins show that thalidomide reduces FGF signalling from the apical ridge [54, 112–114]. This led to the proposal that following thalidomide binding to Cereblon perhaps FGF signalling misregulation may occur in the limb [113, 156]. However the use of an antiangiogenic analog of thalidomide, CPS49, demonstrated reduction and loss of FGF signalling from the limb apical ridge is secondary to the loss of blood vessels and the induction of mesenchymal cell death [54]. In addition, the embryonic expression pattern of Cereblon is unclear. Presently, reports suggest Cereblon may be ubiquitously expressed in human and mouse tissues [113]. How Cereblon binding to thalidomide can lead to the time sensitive and tissue specific defects associated with thalidomide embryopathy remains unclear. Furthermore, a recent study investigating Cereblon function generated a loss-of-function mutant mouse line (where the gene was inactivated throughout the mouse). The study reports that Cereblon is a negative modulator of AMP-activated protein kinase (AMPK), leading to protection against enhanced weight gain in high fat diets [155]. Strikingly, the mice have no apparent change in limb morphology or facial morphology, in fact the mice appear physically and morphologically normal, though whether the mice suffered from mental disabilities or late onset morphological problems was not reported [155].

Further studies are required to determine Cereblon's role in teratogenesis.

7.2. Actin Cytoskeleton. Thalidomide, lenalidomide, and CPS49 have each been shown to affect the actin cytoskeleton and cell migratory ability of endothelial cells [54, 85, 121, 157, 158]. Actin is upregulated and tubulin is downregulated, indicating cells can not proliferate nor migrate. Indeed filopodial extensions from migrating endothelial cells are inhibited, following CPS49 exposure, preventing vascular tube formation [54]. Could a molecular target of thalidomide in endothelial cells be the actin cytoskeleton? A GeneChip Array screen of monkey fetuses exposed to thalidomide indicated a high number of vascular and cytoskeletal marker changes [159]. Whether these are primary or secondary targets remains to be determined.

7.3. Nitric Oxide. Nitric oxide has a role in blood vessel protection and has been shown to be able to rescue thalidomide-induced damage [119, 122]. A recent study looking at human thalidomide survivors indicated survivors have a higher frequency of polymorphisms associated with reduced Nitric

oxide expression, suggesting individuals with such a genotype could be more susceptible to thalidomide damage [160], perhaps due to reduced protection of blood vessels.

7.4. Molecular Screens. Recently proteomic and transcriptomic screens of thalidomide treated human embryonic stem cells and GeneChip Array and Bioinformatics screens of thalidomide treated cynomolgus monkey fetuses have looked for molecular targets of thalidomide [159, 161]. In the human cell lines changes in limb, heart, nerve and embryonic signaling molecules were uncovered [161]. Strikingly more than 2000 gene profiles were changed in the monkey tissue with the majority being related to actin cytoskeleton, the vasculature and inflammatory response [159]. Together these screens indicate there are many potential targets of thalidomide.

Altogether and as described earlier in this Review, many genes and molecular pathways have already been linked to, or even shown to have changed gene expression patterns following thalidomide exposure. The challenge now is to determine the precise order and number of the molecular targets and downstream signaling events and how they lead to teratogenesis. Determining the molecular targets of thalidomide that result in teratogenesis could help develop forms of the drug that retain clinical relevance without the teratogenic side-effect.

8. Framework of Thalidomide Teratogenicity

A model underlying the mechanism of thalidomide-induced teratogenesis needs to explain the time-sensitive action of the drug on all tissues, including, limbs; ears; eyes; facial, internal organ; and genitalia.

All of the models proposed to explain thalidomide embryopathy are not necessarily mutually exclusive and to some extent each of these models can explain an aspect of Thalidomide embryopathy. Effects upon the vasculature have been demonstrated to cause embryonic defect [34, 54, 119, 121, 123] and molecules involved in vascular development are changed following thalidomide exposure [102, 119, 121, 123, 159–161]. Furthermore, the antiangiogenic analog of thalidomide, CPS49, acts in a time sensitive manner in the chick embryo [54]. The action of thalidomide upon blood vessels, together with evidence that birth defects can be caused by damaging blood vessels either through drug exposure, for example, sodium valproate [124] or by genetic ablation, for example, in zebrafish [106], suggests the triggering event leading to thalidomide embryopathy could well be blood vessels. Thus, at this point, angiogenesis could be the triggering event and by putting together the other models we can produce a framework from exposure to defect and further consequences (Figure 4). What remains unclear is the molecular target(s).

Thalidomide breaks down into a range of byproducts through metabolism and hydrolysis [29]; the antiangiogenic byproduct causes teratogenesis [1, 2, 54]. Blood vessels are essential for the development of tissues and organs [100]. Exposure to thalidomide during periods of rapid angiogenesis and tissue formation results in vascular formation failure, induction of cell death and ROS in cells requiring

oxygen and nutrients, and gene expression changes. Such exposure during early limb formation, or when tissues/organs are rapidly forming, is devastating. If the antiangiogenic insult occurs earlier in development, when all vessels are angiogenic and all the major tissues and organs are forming, this could result in cell death in the tissue concerned and misexpression of signalling pathways. The resulting loss or misdevelopment of tissue may well be lethal or then result in the failure of the correct recruitment and differentiation of other cell types including nerves, neural crest, chondrocytes muscle (particularly if the tissue was severely damaged, resulting nerve innervation would be severely compromised). This would also impact internal organ function as well as nervous system function, exacerbating the defect in the already damaged tissue (Figure 4).

The Framework would predict that late fetal exposure to thalidomide could damage newly formed/forming blood vessels in the internal organs/tissues as they are growing and maturing preventing proper maturation/growth of the organ or proper function. Such dysfunction may not be detected for some time after birth depending on the amount of damage [1, 2]. Interestingly, a study in rats following late fetal exposure to thalidomide found that the fetal rats had neurological damage in areas of the brain associated with autism, and this appeared due to a loss of blood vessels [44].

9. Species Specificity

It is well known that thalidomide exhibits species-specific differences in its teratogenic actions [1, 3, 8, 129]. Many animal organisms have been used to study thalidomide's actions, including chicks, rabbits, zebrafish, marine fish, armadillos, marsupials, hydra, and nonhuman primates [1, 2, 44, 54, 121, 123, 159, 162–165]. One of the surprising aspects of thalidomide is that rodent embryos are less sensitive to thalidomide with varying results of activity as well as being mouse strain specific [166] and as such customarily are not seen as a primary tool to study thalidomide induced teratogenesis [165, 167–174]. In fact the thalidomide disaster of 1957–61 indicated, for the first time, that species differences exist in the reaction to drugs.

Rabbits and nonhuman primates, though useful, have small litter sizes (and rabbits also resorb malformed fetuses *in utero* making it difficult sometimes to determine the full range of damage, etc.) requiring large numbers of animals to be used. Furthermore, the action of the drug (as well as the timing and range of damage) cannot be followed “*in vivo*” in the living embryo of rabbits, rodents, marsupials, and nonhuman primates. Embryo cultures of rabbit embryos indicate thalidomide and its breakdown products teratogenic actions can be studied *in vitro* [175]. In addition, despite rodents being less sensitive to thalidomide, mouse embryo cultures following thalidomide exposure have been carried out and typically such embryos survive up to 2 days and exhibit thalidomide-like damage [116, 166]. Although these embryo culture techniques are very useful and informative, it can be difficult to determine the precise range of damage to the limbs and other tissues as the cultures do not develop

consistently further than around 2 days. Efforts to improve the length of time mouse and rabbit embryos can be cultured *in vitro* would be a major advance. Specifically allowing the genetic tractability of the mouse to be used to understand molecular targets of thalidomide in more detail. Chick and zebrafish embryos offer good models to study drug action and toxicity on limb and embryonic development and to follow the effects “live” and have been widely used [54, 85, 113, 114, 117, 121, 123, 124, 176, 177].

Species-specific differences in teratogenic action are also apparent for lenalidomide and pomalidomide. Lenalidomide is nonteratogenic in rabbits [178] but is in chick and zebrafish embryos [85] and in monkeys. In contrast pomalidomide is not teratogenic in chick and zebrafish embryos [85] yet is teratogenic in rats and rabbits [86] (http://www.accessdata.fda.gov/drugsatfda_docs/label/2013/2040261bl.pdf).

What are the reasons for these species differences in activity? Many theories have been proposed, including metabolism differences between the species. Thalidomide has more antiangiogenic activity following incubation with human and rabbit liver microsomes than rat microsomes [92, 93]. Whether the teratogenic breakdown products of thalidomide are made in the mouse embryo or are present long enough is also unclear as clearance of the drug is extremely rapid in mice compared with humans [179, 180]. To add further complexity to the issue, thalidomide treated with rat liver homogenate can cause embryotoxicity in chick embryos suggesting that even though rat liver is not as effective as human and rabbit in thalidomide metabolism, the enzymes are present [181]. Metabolic clearance rates may differ between species, meaning teratogenic forms of the drug may not be present for long. Placental transport differences could also exist between species. It remains unclear how the drugs gain access to cells, whether through a receptor or transport channel.

9.1. Glutathione and ROS Differences. A study reported that mouse embryonic fibroblasts have high levels of glutathione which inhibit superoxide formation and thus prevent ROS formation and prevent cell death induction [182]. In contrast human cell lines have low levels of glutathione and are suggested to be more able to produce ROS following thalidomide exposure [120, 182]. Likewise mice embryos suffer from thalidomide-induced embryopathies when glutathione is depleted [140]. As discussed earlier, production of ROS leads to cell death and embryopathy but how the time sensitive and tissue specific actions come about requires further study. As depleting glutathione makes mouse embryos sensitive to thalidomide, perhaps this is one method to potentially open the mouse embryo up for thalidomide teratogenesis studies [140, 182].

Understanding the basis of species specificity may help understand how to make improved or alternative drugs that cannot cause teratogenesis or perhaps make forms of the drug that cant break down into teratogenic byproducts.

9.2. Screening for Safer and Nonteratogenic Forms of Thalidomide. Clearly thalidomide and its licensed sister compounds,

lenalidomide and pomalidomide, are clinically useful, particularly for treatment of multiple myeloma. However, they retain nasty and unwanted side-effects. We still do not fully understand how these side effects are caused or come about. Moreover, administering a compound that exerts anti-inflammatory and antiangiogenic effects for an inflammatory condition is not desirable. What would be therapeutically more effective would be to retain the clinically relevant aspects of the drug and lose the bad aspects and also to have more targeted and tissue specific versions. Can this be done?

The antiangiogenic action of thalidomide has been demonstrated to cause teratogenesis in chick and zebrafish embryos [1, 54]. It is also known that lenalidomide and pomalidomide also have antiangiogenic properties in rodent assays and myeloma cell lines [157, 158, 183, 184]. Lenalidomide is also antiangiogenic (and teratogenic) in chicken and zebrafish embryos, whereas pomalidomide is not [85]. Precisely what the molecular targets of these compounds are remains unclear. The nature of the species-specific differences in action is also unclear. However this indicates that the antiangiogenic action of these compounds likely underlies their teratogenic activities. Producing versions of the drug or alternative drugs without the antiangiogenic actions but retaining anti-inflammatory actions could, ultimately, following testing in higher species and clinical trials, produce a compound retaining clinical benefit for treatment of inflammatory disorders with reduced side effect.

Indeed, some non-antiangiogenic analogs and hydrolytic break down products of thalidomide have been shown to be nonteratogenic in chicken embryos [54]. This indicates the possibility that screening other structural analogs of thalidomide could lead to identifying compounds with specific actions with reduced or lessened side effects. Further work is required to elucidate analogs/derivatives that are purely anti-inflammatory or purely antiangiogenic. Such analogs/derivatives could initially be screened in embryonic systems as well as *in vitro* assays to investigate their effects/actions upon angiogenesis, inflammation, teratogenicity, and nerve function. Identification of such compounds could mean, after further testing and screening in mammalian and human model assays, potentially more targeted compounds to treat inflammatory disorders without the spectre of birth defect or peripheral neuropathy but also to treat cancers without the side effect of dampening down the inflammatory system.

10. Conclusion

How thalidomide causes birth defects has puzzled scientists and clinicians alike since the first cases of thalidomide embryopathy were described between 1958 and 1961. Thalidomide remains an enigma in many respects. Thalidomide caused the biggest medical disaster of all time, founded the field of modern toxicology, and changed forever the ways drugs are tested. Yet, we still do not fully understand how this drug caused the range and severity of birth defects, nor do we understand the drug's species specific differences in action. Thalidomide has important functions in the inflammatory

and vascular tissues and it is also unclear how precisely the drug acts in these tissues.

In the past decade great progress has been made in elucidating the mechanisms underlying thalidomide embryopathy and its targets and making safer forms of the drug. Thalidomide and its analogs, lenalidomide and pomalidomide, are used to treat multiple myeloma and leprosy. Thalidomide is also used to treat Crohn's disease, Behcet's disease, HIV, and cancers. But they still have serious side effects, such as peripheral neuropathy. And tragically thalidomide embryopathy still occurs, particularly in Brazil. Understanding how thalidomide causes birth defect remains important to determine as does how it treats the conditions it is successful in. Ultimately this information will help to make safer forms of the drug targeted for specific conditions without the side effects.

Thalidomide's action on the forming vasculature causes limb defects and likely damages other tissues through destroying vessels as tissues are forming, growing and requiring a vasculature. By uniting the many models suggested for thalidomide embryopathy, a framework of thalidomide teratogenesis can be produced which acts as a template for effects on all the other tissues affected by thalidomide.

Yet significant challenges remain, specifically understanding the molecular target/s and/or sequence of events resulting in thalidomide embryopathy and determining the basis of species specificity differences in the action of drug. Furthermore, given the actions of the drug on different pathways, understanding how to modulate these for the benefit of the patient to make safer and tissue specific/targeted versions of the drug remains an important goal.

Finally, how does thalidomide induce phocomelia (loss of proximal elements)? Does it arise through a recovery of apical ridge signalling, after loss of limb mesenchyme, distalising the remaining mesenchyme? Or could the early loss of blood vessels and cell death induction directly interfere with cartilage condensation/ossification processes resulting in shortened/missing proximal elements. Or could phocomelia arise due to changes in limb patterning signalling where distal markers come on earlier than normal in the damaged limb? Understanding the mechanisms underlying phocomelia will also help further understanding on normal mechanisms controlling proximodistal patterning of the limb bud.

Conflict of Interests

The author declares there is no conflict of interests.

Acknowledgments

Thanks go to Dr. Chris Mahony, Prof. Martin Collinson, Shaunna-Leigh Beedie and Alexandra Diamond for critical comments on the paper. Thanks also go to Prof. Lynda Erskine, Dr. W. D. Figg, Dr. Lavinia Schuler-Faccini, Dr. Robert L. Smith, Prof. Nigel Brown, Prof. Ruth Ross, Prof. Cheryll Tickle and Prof. Lewis Wolpert for fantastic discussions on thalidomide. This work is dedicated to C. G. V. and C. W. M. V.

References

- [1] N. Vargesson, "Thalidomide-induced limb defects: resolving a 50-year-old puzzle," *BioEssays*, vol. 31, no. 12, pp. 1327–1336, 2009.
- [2] N. Vargesson, "Thalidomide," in *Reproductive and Developmental Toxicology*, R. Gupta, Ed., pp. 395–403, Academic Press, Elsevier, Amsterdam, The Netherlands, 2011.
- [3] W. Lenz, "A short history of thalidomide embryopathy," *Teratology*, vol. 38, no. 3, pp. 203–215, 1988.
- [4] S. V. Rajkumar, "Thalidomide: tragic past and promising future," *Mayo Clinic Proceedings*, vol. 79, no. 7, pp. 899–903, 2004.
- [5] F. O. Kelsey, "Events after thalidomide," *Journal of Dental Research*, vol. 46, no. 6, pp. 1201–1205, 1967.
- [6] F. O. Kelsey, "Thalidomide update: regulatory aspects," *Teratology*, vol. 38, no. 3, pp. 221–226, 1988.
- [7] R. W. Smithells and C. G. H. Newman, "Recognition of thalidomide defects," *Journal of Medical Genetics*, vol. 29, no. 10, pp. 716–723, 1992.
- [8] T. D. Stephens, C. J. W. Bunde, and B. J. Fillmore, "Mechanism of action in thalidomide teratogenesis," *Biochemical Pharmacology*, vol. 59, no. 12, pp. 1489–1499, 2000.
- [9] T. Kajii, M. Kida, and K. Takahashi, "The effect of thalidomide intake during 113 human pregnancies," *Teratology*, vol. 8, no. 2, pp. 163–166, 1973.
- [10] T. Kajii and M. Shinohara, "Thalidomide in Japan," *The Lancet*, vol. 1, no. 7279, pp. 501–502, 1963.
- [11] W. Lenz and K. Knapp, "Thalidomide embryopathy," *Archives of Environmental Health*, vol. 5, pp. 100–105, 1962.
- [12] W. G. McBride, "Studies of the etiology of thalidomide dysmorphogenesis," *Teratology*, vol. 14, no. 1, pp. 71–87, 1976.
- [13] C. G. H. Newman, "Clinical observations on the thalidomide syndrome," *Proceedings of the Royal Society of Medicine*, vol. 70, no. 4, pp. 225–227, 1977.
- [14] C. G. H. Newman, "Teratogen update: clinical aspects of thalidomide embryopathy—a continuing preoccupation," *Teratology*, vol. 32, no. 1, pp. 133–144, 1985.
- [15] C. G. H. Newman, "The thalidomide syndrome: risks of exposure and spectrum of malformations," *Clinics in Perinatology*, vol. 13, no. 3, pp. 555–573, 1986.
- [16] R. W. Smithells, "Thalidomide and malformations in liverpool," *The Lancet*, vol. 279, no. 7242, pp. 1270–1273, 1962.
- [17] R. W. Smithells, "Defects and disabilities of thalidomide children," *British medical journal*, vol. 1, no. 5848, pp. 269–272, 1973.
- [18] I. M. Leck and E. L. Millar, "Incidence of malformations since the introduction of thalidomide," *British Medical Journal*, vol. 2, no. 5296, pp. 16–20, 1962.
- [19] H. B. Taussig, "A study of the German outbreak of phocomelia. The thalidomide syndrome," *The journal of the American Medical Association*, vol. 180, pp. 1106–1114, 1962.
- [20] U. K. Government Report, "Deformities caused by Thalidomide," Reports on Public Health and Medical Subjects. : 112, Ministry of Health, HMSO, London, UK, 1964.
- [21] G. F. Somers, "Thalidomide and congenital abnormalities," *The Lancet*, vol. 1, no. 7235, pp. 912–913, 1962.
- [22] R. W. Smithells and I. Leck, "The incidence of limb and ear defects since the withdrawal of thalidomide," *The Lancet*, vol. 1, no. 7290, pp. 1095–1097, 1963.
- [23] B. M. Ances, "New concerns about thalidomide," *Obstetrics and Gynecology*, vol. 99, no. 1, pp. 125–128, 2002.
- [24] F. O. Kelsey, "Drug embryopathy: the thalidomide story," *Maryland State Medical Journal*, vol. 12, pp. 594–597, 1963.
- [25] M. T. Miller and K. Stromland, "Teratogen update: thalidomide: a review, with a focus on ocular findings and new potential uses," *Teratology*, vol. 60, pp. 306–321, 1999.
- [26] H. B. TAUSSIG, "The thalidomide syndrome," *Scientific American*, vol. 207, pp. 29–35, 1962.
- [27] J. Sheskin, "Thalidomide in the Treatment of Leprosy Reactions," *Clinical Pharmacology and Therapeutics*, vol. 6, pp. 303–306, 1965.
- [28] R. J. D'Amato, M. S. Loughnan, E. Flynn, and J. Folkman, "Thalidomide is an inhibitor of angiogenesis," *Proceedings of the National Academy of Sciences of the United States of America*, vol. 91, no. 9, pp. 4082–4085, 1994.
- [29] M. E. Franks, G. R. Macpherson, and W. D. Figg, "Thalidomide," *The Lancet*, vol. 363, no. 9423, pp. 1802–1811, 2004.
- [30] T. Facon, J. Y. Mary, C. Hulin et al., "Melphalan and prednisone plus thalidomide versus melphalan and prednisone alone or reduced-intensity autologous stem cell transplantation in elderly patients with multiple myeloma (IFM 99-06): a randomised trial," *The Lancet*, vol. 370, no. 9594, pp. 1209–1218, 2007.
- [31] A. Palumbo and M. Boccadoro, "A new standard of care for elderly patients with myeloma," *The Lancet*, vol. 370, no. 9594, pp. 1191–1192, 2007.
- [32] B. Ladizinski, E. J. Shannon, M. R. Sanchez, and W. R. Levis, "Thalidomide and analogues: potential for immunomodulation of inflammatory and neoplastic dermatologic disorders," *Journal of Drugs in Dermatology*, vol. 9, no. 7, pp. 814–826, 2010.
- [33] J. J. Wu, D. B. Huang, K. R. Pang, S. Hsu, and S. K. Tying, "Thalidomide: dermatological indications, mechanisms of action and side-effects," *British Journal of Dermatology*, vol. 153, no. 2, pp. 254–273, 2005.
- [34] F. Lebrin, S. Srun, K. Raymond et al., "Thalidomide stimulates vessel maturation and reduces epistaxis in individuals with hereditary hemorrhagic telangiectasia," *Nature Medicine*, vol. 16, no. 4, pp. 420–428, 2010.
- [35] M. R. Horton and R. W. Hallowell, "Revisiting thalidomide: fighting with caution against idiopathic pulmonary fibrosis," *Drugs Today*, vol. 48, pp. 661–671, 2012.
- [36] J. Knobloch, D. Jungck, and A. Koch, "Apoptosis induction by thalidomide: critical for limb teratogenicity but therapeutic potential in idiopathic pulmonary fibrosis?" *Current Molecular Pharmacology*, vol. 4, no. 1, pp. 26–61, 2011.
- [37] E. E. Castilla, P. Ashton-Prolla, E. Barreda-Mejia et al., "Thalidomide, a current teratogen in South America," *Teratology*, vol. 54, pp. 273–277, 1996.
- [38] L. Schuler-Faccini, R. C. F. Soares, A. C. M. de Sousa et al., "New cases of thalidomide embryopathy in Brazil," *Birth Defects Research A*, vol. 79, no. 9, pp. 671–672, 2007.
- [39] F. S. L. Vianna, J. S. Lopez-Camelo, J. C. L. Leite et al., "Epidemiological surveillance of birth defects compatible with thalidomide embryopathy in Brazil," *PLoS ONE*, vol. 6, no. 7, Article ID e21735, 2011.
- [40] F. S. Vianna, L. Schuler-Faccini, J. C. Leite et al., "Recognition of the phenotype of thalidomide embryopathy in countries endemic for leprosy: new cases and review of the main dysmorphic findings," *Clinical Dysmorphology*, vol. 22, pp. 59–63, 2013.
- [41] W. G. McBride, "Thalidomide embryopathy," *Teratology*, vol. 16, no. 1, pp. 79–82, 1977.

- [42] M. T. Miller, K. Strömmland, L. Ventura, M. Johansson, J. M. Bandim, and C. Gillberg, "Autism associated with conditions characterized by developmental errors in early embryogenesis: a mini review," *International Journal of Developmental Neuroscience*, vol. 23, no. 2-3, pp. 201-219, 2005.
- [43] W. H. James, "Teratogenic properties of thalidomide," *British Medical Journal*, vol. 2, no. 5469, p. 1064, 1965.
- [44] K. L. Hallene, E. Oby, B. J. Lee et al., "Prenatal exposure to thalidomide, altered vasculogenesis, and CNS malformations," *Neuroscience*, vol. 142, no. 1, pp. 267-283, 2006.
- [45] M. T. Miller and K. K. Strömmland, "What can we learn from the thalidomide experience: an ophthalmologic perspective," *Current Opinion in Ophthalmology*, vol. 22, no. 5, pp. 356-364, 2011.
- [46] L. Henkel and H. G. Willert, "Dysmelia classification and a pattern of malformation in a group of congenital defects of the limbs," *Journal of Bone and Joint Surgery B*, vol. 51, no. 3, pp. 399-414, 1969.
- [47] A. L. Speirs, "Thalidomide and congenital abnormalities," *The Lancet*, vol. 1, no. 7224, pp. 303-305, 1962.
- [48] I. Leck and R. W. Smithells, "The ascertainment of malformations," *Lancet*, vol. 1, pp. 101-103, 1963.
- [49] J. McCredie and H.-G. Willert, "Longitudinal limb deficiencies and the sclerotomes. An analysis of 378 dysmelic malformations induced by thalidomide," *Journal of Bone and Joint Surgery B*, vol. 81, no. 1, pp. 9-23, 1999.
- [50] K. C. Oberg, J. M. Feenstra, P. R. Manske, and M. A. Tonkin, "Developmental biology and classification of congenital anomalies of the hand and upper extremity," *Journal of Hand Surgery*, vol. 35, no. 12, pp. 2066-2076, 2010.
- [51] M. Towers and C. Tickle, "Generation of pattern and form in the developing limb," *International Journal of Developmental Biology*, vol. 53, no. 5-6, pp. 805-812, 2009.
- [52] A. Zuniga, R. Zeller, and S. Probst, "The molecular basis of human congenital limb malformations," *Wiley Interdisciplinary Reviews: Developmental Biology*, vol. 1, pp. 803-822, 2012.
- [53] K. C. Oberg, T. E. Harris, M. D. Wongworawat, and V. E. Wood, "Combined congenital radial and ulnar longitudinal deficiencies: report of 2 cases," *Journal of Hand Surgery*, vol. 34, no. 7, pp. 1298-1302, 2009.
- [54] C. Therapontos, L. Erskine, E. R. Gardner, W. D. Figg, and N. Vargesson, "Thalidomide induces limb defects by preventing angiogenic outgrowth during early limb formation," *Proceedings of the National Academy of Sciences of the United States of America*, vol. 106, no. 21, pp. 8573-8578, 2009.
- [55] M. Schmidt and F. M. Salzano, "Dissimilar effects of thalidomide in dizygotic twins," *Acta Geneticae Medicae et Gemellologiae*, vol. 29, no. 4, pp. 295-297, 1980.
- [56] R. J. Newman, "Shoulder joint replacement for osteoarthritis in association with thalidomide-induced phocomelia," *Clinical Rehabilitation*, vol. 13, no. 3, pp. 250-252, 1999.
- [57] L. Ruffing, "Evaluation of thalidomide children," *Birth Defects*, vol. 13, no. 1, pp. 287-300, 1977.
- [58] J. F. Cullen, "Ocular defects in thalidomide babies," *British Journal of Ophthalmology*, vol. 48, pp. 151-153, 1964.
- [59] R. Cuthbert and A. L. Speirs, "Thalidomide induced malformations—a radiological survey," *Clinical Radiology*, vol. 14, no. 2, pp. 163-169, 1963.
- [60] G. Livingstone, "Congenital ear abnormalities due to thalidomide," *Proceedings of the Royal Society of Medicine*, vol. 58, pp. 493-497, 1965.
- [61] C. G. D. Brook, S. N. Jarvis, and C. G. H. Newman, "Linear growth of children with limb deformities following exposure to thalidomide in utero," *Acta Paediatrica Scandinavica*, vol. 66, no. 6, pp. 673-675, 1977.
- [62] G. Chamberlain, "The obstetric problems of the thalidomide children," *British Medical Journal*, vol. 298, no. 6665, p. 6, 1989.
- [63] I. Fletcher, "Review of the treatment of thalidomide children with limb deficiency in great Britain," *Clinical Orthopaedics and Related Research*, vol. 148, pp. 18-25, 1980.
- [64] B. J. Soules, "Thalidomide victims in a rehabilitation center," *Ha-Ahot be-Yisrael*, vol. 12, no. 60, pp. 43-45, 1966.
- [65] J. M. Hansen and C. Harris, "Redox control of teratogenesis," *Reproductive Toxicology*, vol. 35, pp. 165-179, 2013.
- [66] J. Ashby and H. Tinwell, "Thalidomide is not a human mutagen," *British Medical Journal*, vol. 325, no. 7374, p. 1245, 2002.
- [67] J. Kohlhase and L. B. Holmes, "Mutations in SALL4 in malformed father and daughter postulated previously due to reflect mutagenesis by thalidomide," *Birth Defects Research A*, vol. 70, no. 8, pp. 550-551, 2004.
- [68] J. Kohlhase, L. Schubert, M. Liebers et al., "Mutations at the SALL4 locus on chromosome 20 result in a range of clinically overlapping phenotypes, including Okihiro syndrome, Holt-Oram syndrome, acro-renal-ocular syndrome, and patients previously reported to represent thalidomide embryopathy," *Journal of Medical Genetics*, vol. 40, no. 7, pp. 473-478, 2003.
- [69] A. W. Bates, "A case of Roberts syndrome described in 1737," *Journal of Medical Genetics*, vol. 38, no. 8, pp. 565-567, 2001.
- [70] E. S.-Y. Goh, C. Li, S. Horsburgh, Y. Kasai, E. Kolomietz, and C. F. Morel, "The Roberts syndrome/SC phocomelia spectrum—a case report of an adult with review of the literature," *American Journal of Medical Genetics A*, vol. 152, no. 2, pp. 472-478, 2010.
- [71] B. Schüle, A. Oviedo, K. Johnston, S. Pai, and U. Francke, "Inactivating mutations in ESCO2 cause SC phocomelia and Roberts syndrome: no phenotype-genotype correlation," *American Journal of Human Genetics*, vol. 77, no. 6, pp. 1117-1128, 2005.
- [72] H. Vega, Q. Waisfisz, M. Gordillo et al., "Roberts syndrome is caused by mutations in ESCO2, a human homolog of yeast ECO1 that is essential for the establishment of sister chromatid cohesion," *Nature Genetics*, vol. 37, no. 5, pp. 468-470, 2005.
- [73] M. Mönnich, Z. Kuriger, C. G. Print, and J. A. Horsfield, "A zebrafish model of roberts syndrome reveals that Esco2 depletion interferes with development by disrupting the cell cycle," *PLoS ONE*, vol. 6, no. 5, Article ID e20051, 2011.
- [74] G. Whelan, E. Kreidl, J. M. Peters, and G. Eichele, "The non-redundant function of cohesin acetyltransferase Esco2: some answers and new questions," *Nucleus*, vol. 3, pp. 330-334, 2012.
- [75] S. Cundari and G. Cavaletti, "Thalidomide chemotherapy-induced peripheral neuropathy: actual status and new perspectives with thalidomide analogues derivatives," *Mini-Reviews in Medicinal Chemistry*, vol. 9, no. 7, pp. 760-768, 2009.
- [76] M. Delforge, J. Bladé, M. A. Dimopoulos et al., "Treatment-related peripheral neuropathy in multiple myeloma: the challenge continues," *The Lancet Oncology*, vol. 11, no. 11, pp. 1086-1095, 2010.
- [77] F. O. Kelsey, "Problems raised for the FDA by the occurrence of thalidomide embryopathy in Germany, 1960-1961," *American Journal of Public Health and the Nation's Health*, vol. 55, pp. 703-707, 1965.
- [78] A. C. Peltier and J. W. Russell, "Advances in understanding drug-induced neuropathies," *Drug Safety*, vol. 29, no. 1, pp. 23-30, 2006.

- [79] P. G. Richardson, M. Delforge, M. Beksac et al., "Management of treatment-emergent peripheral neuropathy in multiple myeloma," *Leukemia*, vol. 26, no. 4, pp. 595–608, 2012.
- [80] M. S. Raab, K. Podar, I. Breitkreutz, P. G. Richardson, and K. C. Anderson, "Multiple myeloma," *The Lancet*, vol. 374, no. 9686, pp. 324–339, 2009.
- [81] M. Q. Lacy, S. R. Hayman, M. A. Gertz et al., "Pomalidomide (CC4047) plus low-dose dexamethasone as therapy for relapsed multiple myeloma," *Journal of Clinical Oncology*, vol. 27, no. 30, pp. 5008–5014, 2009.
- [82] P. G. Richardson, D. Siegel, R. Baz et al., "Phase 1 study of pomalidomide MTD, safety, and efficacy in patients with refractory multiple myeloma who have received lenalidomide and bortezomib," *Blood*, vol. 121, pp. 1961–1967, 2013.
- [83] A. Palumbo, J. Freeman, L. Weiss, and P. Fenaux, "The clinical safety of lenalidomide in multiple myeloma and myelodysplastic syndromes," *Expert Opinion on Drug Safety*, vol. 11, no. 1, pp. 107–120, 2012.
- [84] P. M. Voorhees, J. Laubach, K. C. Anderson, and P. G. Richardson, "Peripheral neuropathy in multiple myeloma patients receiving lenalidomide, bortezomib, and dexamethasone (RVD) therapy," *Blood*, vol. 121, article 858, 2013.
- [85] C. Mahony, L. Erskine, J. Niven et al., "Pomalidomide is nonteratogenic in chicken and zebrafish embryos and nonneurotoxic invitro," *Proceedings of the National Academy of Sciences of the United States of America*, vol. 110, pp. 12703–12708, 2013.
- [86] R. L. Smith, S. Fabro, H. Schumacher, and R. T. Williams, "Studies on the relationship between the chemical structure and embryotoxic activity of thalidomide and related compounds," in *Embryopathic Activity of Drugs*, J. M. Robson, F. Sullivan, and R. L. Smith, Eds., pp. 194–209, Churchill, London, UK, 1965.
- [87] C. P. Castaneda, J. B. Zeldis, J. Freeman, C. Quigley, N. A. Brandenburg, and R. Bwire, "RevAssist: a comprehensive risk minimization programme for preventing fetal exposure to lenalidomide," *Drug Safety*, vol. 31, no. 9, pp. 743–752, 2008.
- [88] K. Uhl, E. Cox, R. Rogan et al., "Thalidomide use in the US: experience with pregnancy testing in the S.T.E.P.S. programme," *Drug Safety*, vol. 29, no. 4, pp. 321–329, 2006.
- [89] J. B. Zeldis, B. A. Williams, S. D. Thomas, and M. E. Elsayed, "S.T.E.P.S.: a comprehensive program for controlling and monitoring access to thalidomide," *Clinical Therapeutics*, vol. 21, no. 2, pp. 319–330, 1999.
- [90] J. B. Bartlett, K. Dredge, and A. G. Dalglish, "The evolution of thalidomide and its IMiD derivatives as anticancer agents," *Nature Reviews Cancer*, vol. 4, no. 4, pp. 314–322, 2004.
- [91] C. Galustian, M.-C. Labarthe, J. B. Bartlett, and A. G. Dalglish, "Thalidomide-derived immunomodulatory drugs as therapeutic agents," *Expert Opinion on Biological Therapy*, vol. 4, no. 12, pp. 1963–1970, 2004.
- [92] K. S. Bauer, S. C. Dixon, and W. D. Figg, "Inhibition of angiogenesis by thalidomide requires metabolic activation, which is species-dependent," *Biochemical Pharmacology*, vol. 55, no. 11, pp. 1827–1834, 1998.
- [93] M. G. Marks, J. Shi, M. O. Fry et al., "Effects of putative hydroxylated thalidomide metabolites on blood vessel density in the chorioallantoic membrane (CAM) assay and on tumor and endothelial cell proliferation," *Biological and Pharmaceutical Bulletin*, vol. 25, no. 5, pp. 597–604, 2002.
- [94] A. L. Moreira, E. P. Sampaio, A. Zmuidzinis, P. Frindt, K. A. Smith, and G. Kaplan, "Thalidomide exerts its inhibitory action on tumor necrosis factor α by enhancing mRNA degradation," *Journal of Experimental Medicine*, vol. 177, no. 6, pp. 1675–1680, 1993.
- [95] F. Payvandi, L. Wu, M. Haley et al., "Immunomodulatory drugs inhibit expression of cyclooxygenase-2 from TNF- α , IL-1 β , and LPS-stimulated human PBMC in a partially IL-10-dependent manner," *Cellular Immunology*, vol. 230, no. 2, pp. 81–88, 2004.
- [96] T. Hideshima, D. Chauhan, Y. Shima et al., "Thalidomide and its analogs overcome drug resistance of human multiple myeloma cells to conventional therapy," *Blood*, vol. 96, no. 9, pp. 2943–2950, 2000.
- [97] W. Luo, Q.-S. Yu, I. Salcedo et al., "Design, synthesis and biological assessment of novel N-substituted 3-(phthalimidin-2-yl)-2,6-dioxopiperidines and 3-substituted 2,6-dioxopiperidines for TNF- α inhibitory activity," *Bioorganic and Medicinal Chemistry*, vol. 19, no. 13, pp. 3965–3972, 2011.
- [98] D. Ribatti, G. Mangialardi, and A. Vacca, "Antiangiogenic therapeutic approaches in multiple myeloma," *Current Cancer Drug Targets*, vol. 12, pp. 768–775, 2012.
- [99] P. Carmeliet, N. Mackman, L. Moons et al., "Role of tissue factor in embryonic blood vessel development," *Nature*, vol. 383, no. 6595, pp. 73–75, 1996.
- [100] N. Vargesson, "Vascularization of the developing chick limb bud: role of The TGF β signalling pathway," *Journal of Anatomy*, vol. 202, no. 1, pp. 93–103, 2003.
- [101] E. Crivellato, "The role of angiogenic growth factors in organogenesis," *International Journal of Developmental Biology*, vol. 55, no. 4–5, pp. 365–375, 2011.
- [102] T. B. Knudsen and N. C. Kleinstreuer, "Disruption of embryonic vascular development in predictive toxicology," *Birth Defects Research C*, vol. 93, no. 4, pp. 312–323, 2012.
- [103] H. Chang, D. Huylebroeck, K. Verschueren, Q. Guo, M. M. Matzuk, and A. Zwijsen, "Smad5 knockout mice die at mid-gestation due to multiple embryonic and extraembryonic defects," *Development*, vol. 126, no. 8, pp. 1631–1642, 1999.
- [104] N. Ferrara, K. Carver-Moore, H. Chen et al., "Heterozygous embryonic lethality induced by targeted inactivation of the VEGF gene," *Nature*, vol. 380, no. 6573, pp. 439–442, 1996.
- [105] F. Shalaby, J. Rossant, T. P. Yamaguchi et al., "Failure of blood-island formation and vasculogenesis in Flk-1 deficient mice," *Nature*, vol. 376, no. 6535, pp. 62–66, 1995.
- [106] J. D. Leslie, L. Ariza-McNaughton, A. L. Bermange, R. McAdow, S. L. Johnson, and J. Lewis, "Endothelial signalling by the Notch ligand Delta-like 4 restricts angiogenesis," *Development*, vol. 134, no. 5, pp. 839–844, 2007.
- [107] C. Therapontos and N. Vargesson, "Zebrafish notch signalling pathway mutants exhibit trunk vessel patterning anomalies that are secondary to somite misregulation," *Developmental Dynamics*, vol. 239, no. 10, pp. 2761–2768, 2010.
- [108] B. M. Kenyon, F. Browne, and R. J. D'Amato, "Effects of thalidomide and related metabolites in a mouse corneal model of neovascularization," *Experimental Eye Research*, vol. 64, no. 6, pp. 971–978, 1997.
- [109] E. R. Lepper, N. F. Smith, M. C. Cox, C. D. Scripture, and W. D. Figg, "Thalidomide metabolism and hydrolysis: mechanisms and implications," *Current Drug Metabolism*, vol. 7, no. 6, pp. 677–685, 2006.
- [110] N. A. Warfel, E. R. Lepper, C. Zhang, W. D. Figg, and P. A. Dennis, "Importance of the stress kinase p38 α in mediating the direct cytotoxic effects of the Thalidomide analogue, CPS49, in cancer cells and endothelial cells," *Clinical Cancer Research*, vol. 12, pp. 3502–3509, 2006.

- [111] S. S. W. Ng, M. Gütschow, M. Weiss et al., "Antiangiogenic activity of N-substituted and tetrafluorinated thalidomide analogues," *Cancer Research*, vol. 63, no. 12, pp. 3189–3194, 2003.
- [112] J. M. Hansen, S.-G. Gong, M. Philbert, and C. Harris, "Misregulation of gene expression in the redox-sensitive NF- κ B-dependent limb outgrowth pathway by thalidomide," *Developmental Dynamics*, vol. 225, no. 2, pp. 186–194, 2002.
- [113] T. Ito, H. Ando, T. Suzuki et al., "Identification of a primary target of thalidomide teratogenicity," *Science*, vol. 327, no. 5971, pp. 1345–1350, 2010.
- [114] J. Knobloch, J. D. Shaughnessy Jr., and U. Rütther, "Thalidomide induces limb deformities by perturbing the Bmp/Dkk1/Wnt signaling pathway," *The FASEB Journal*, vol. 21, no. 7, pp. 1410–1421, 2007.
- [115] N. Vargesson and E. Laufer, "Smad7 misexpression during embryonic angiogenesis causes vascular dilation and malformations independently of vascular smooth muscle cell function," *Developmental Biology*, vol. 240, no. 2, pp. 499–516, 2001.
- [116] C. J. J. Lee, N. Shibata, M. J. Wiley, and P. G. Wells, "Fluorothalidomide: a characterization of maternal and developmental toxicity in rabbits and mice," *Toxicological Sciences*, vol. 122, no. 1, pp. 157–169, 2011.
- [117] J. Boylen, H. Horne, and W. Johnson, "Teratogenic effects of thalidomide and related substances," *The Lancet*, vol. 1, p. 552, 1963.
- [118] J. Knobloch, I. Schmitz, K. Götz, K. Schulze-Osthoff, and U. Rütther, "Thalidomide induces limb anomalies by PTEN stabilization, Akt suppression, and stimulation of caspase-dependent cell death," *Molecular and Cellular Biology*, vol. 28, no. 2, pp. 529–538, 2008.
- [119] J. H. Siamwala, V. Veeriah, M. K. Priya et al., "Nitric oxide rescues thalidomide mediated teratogenicity," *Scientific Reports*, vol. 2, article 679, 2012.
- [120] J. M. Hansen, K. K. Harris, M. A. Philbert, and C. Harris, "Thalidomide modulates nuclear redox status and preferentially depletes glutathione in rabbit limb versus rat limb," *Journal of Pharmacology and Experimental Therapeutics*, vol. 300, no. 3, pp. 768–776, 2002.
- [121] K. P. Tamilarasan, G. K. Kolluru, M. Rajaram, M. Indhumathy, R. Saranya, and S. Chatterjee, "Thalidomide attenuates nitric oxide mediated angiogenesis by blocking migration of endothelial cells," *BMC Cell Biology*, vol. 7, article 17, 2006.
- [122] S. Majumder, M. Rajaram, A. Muley et al., "Thalidomide attenuates nitric oxide-driven angiogenesis by interacting with soluble guanylyl cyclase," *British Journal of Pharmacology*, vol. 158, no. 7, pp. 1720–1734, 2009.
- [123] T. Yabu, H. Tomimoto, Y. Taguchi, S. Yamaoka, Y. Igarashi, and T. Okazaki, "Thalidomide-induced antiangiogenic action is mediated by ceramide through depletion of VEGF receptors, and is antagonized by sphingosine-1-phosphate," *Blood*, vol. 106, no. 1, pp. 125–134, 2005.
- [124] A. I. Whitsel, C. B. Johnson, and C. J. Forehand, "An in ovo chicken model to study the systemic and localized teratogenic effects of valproic acid," *Teratology*, vol. 66, no. 4, pp. 153–163, 2002.
- [125] J. M. Hansen and C. Harris, "A novel hypothesis for thalidomide-induced limb teratogenesis: redox misregulation of the NF- κ B pathway," *Antioxidants and Redox Signaling*, vol. 6, no. 1, pp. 1–14, 2004.
- [126] R. Neubert, N. Hinz, R. Thiel, and D. Neubert, "Downregulation of adhesion receptors on cells of primate embryos as a probable mechanism of the teratogenic action of thalidomide," *Life Sciences*, vol. 58, no. 4, pp. 295–316, 1995.
- [127] A. Vacca, C. Scavelli, V. Montefusco et al., "Thalidomide downregulates angiogenic genes in bone marrow endothelial cells of patients with active multiple myeloma," *Journal of Clinical Oncology*, vol. 23, no. 23, pp. 5334–5346, 2005.
- [128] T. D. Stephens, "Proposed mechanisms of action in thalidomide embryopathy," *Teratology*, vol. 38, no. 3, pp. 229–239, 1988.
- [129] T. D. Stephens and B. J. Fillmore, "Hypothesis: thalidomide embryopathy-proposed mechanism of action," *Teratology*, vol. 61, pp. 189–195, 2000.
- [130] J. McCredie, "History, heresy and radiology in scientific discovery," *Journal of Medical Imaging and Radiation Oncology*, vol. 53, no. 5, pp. 433–441, 2009.
- [131] J. McCredie and W. G. McBride, "Some congenital abnormalities: possibly due to embryonic peripheral neuropathy," *Clinical Radiology*, vol. 24, no. 2, pp. 204–211, 1973.
- [132] F. Edom-Vovard, B. Schuler, M.-A. Bonnin, M.-A. Teillet, and D. Duprez, "Fgf4 positively regulates scleraxis and tenascin expression in chick limb tendons," *Developmental Biology*, vol. 247, no. 2, pp. 351–366, 2002.
- [133] T. Fukuda, S. Takeda, R. Xu et al., "Sema3A regulates bone-mass accrual through sensory innervations," *Nature*, vol. 497, pp. 490–493, 2013.
- [134] S. Harsum, J. D. W. Clarke, and P. Martin, "A reciprocal relationship between cutaneous nerves and repairing skin wounds in the developing chick embryo," *Developmental Biology*, vol. 238, no. 1, pp. 27–39, 2001.
- [135] T. R. Strecker and T. D. Stephens, "Peripheral nerves do not play a trophic role in limb skeletal morphogenesis," *Teratology*, vol. 27, no. 2, pp. 159–167, 1983.
- [136] G. J. Swanson, "Paths taken by sensory nerve fibres in aneural chick wing buds," *Journal of Embryology and Experimental Morphology*, vol. 86, pp. 109–124, 1985.
- [137] P. Martin and J. Lewis, "Origins of the neurovascular bundle: interactions between developing nerves and blood vessels in embryonic chick skin," *International Journal of Developmental Biology*, vol. 33, no. 3, pp. 379–387, 1989.
- [138] T. Parman, M. J. Wiley, and P. G. Wells, "Free radical-mediated oxidative dna damage in the mechanism of thalidomide teratogenicity," *Nature Medicine*, vol. 5, no. 5, pp. 582–585, 1999.
- [139] P. G. Wells, G. P. McCallum, C. S. Chen et al., "Oxidative stress in developmental origins of disease: teratogenesis, neurodevelopmental deficits, and cancer," *Toxicological Sciences*, vol. 108, no. 1, pp. 4–18, 2009.
- [140] P. G. Wells, Y. Bhuller, C. S. Chen et al., "Molecular and biochemical mechanisms in teratogenesis involving reactive oxygen species," *Toxicology and Applied Pharmacology*, vol. 207, no. 2, pp. S354–S366, 2005.
- [141] J. L. Galloway, I. Delgado, M. A. Ros, and C. J. Tabin, "A reevaluation of X-irradiation-induced phocomelia and proximodistal limb patterning," *Nature*, vol. 460, no. 7253, pp. 400–404, 2009.
- [142] L. Wolpert, C. Tickle, and M. Sampford, "The effect of cell killing by X-irradiation on pattern formation in the chick limb," *Journal of Embryology and Experimental Morphology*, vol. 50, pp. 175–198, 1979.
- [143] A. Barasa, "On the regulative capacity of the chick embryo limb bud," *Experientia*, vol. 20, no. 8, p. 443, 1964.
- [144] A. Hornbruch, *Abnormalities Along the Proximo-Distal Axis of the Chick Wing Bud: the Effect of Surgical Intervention*, Walter de Gruyter, Berlin, Germany, 1980.

- [145] C. Mahony, “Vargesson N. Molecular analysis of regulative events in the developing chick limb,” *Journal of Anatomy*, vol. 223, pp. 1–13, 2013.
- [146] F. V. Mariani, C. P. Ahn, and G. R. Martin, “Genetic evidence that FGFs have an instructive role in limb proximal-distal patterning,” *Nature*, vol. 453, no. 7193, pp. 401–405, 2008.
- [147] D. E. Hague, J. R. Idle, S. C. Mitchell, and R. L. Smith, “Racemates revisited: heterochiral assemblies and the example of DL-thalidomide,” *Xenobiotica*, vol. 41, no. 10, pp. 837–843, 2011.
- [148] N. A. Jönsson, “Chemical structure and teratogenic properties. IV. An outline of a chemical hypothesis for the teratogenic action of thalidomide,” *Acta Pharmaceutica Suecica*, vol. 9, no. 6, pp. 543–562, 1972.
- [149] J. Ashby, H. Tinwell, R. D. Callander et al., “Thalidomide: lack of mutagenic activity across phyla and genetic endpoints,” *Mutation Research*, vol. 396, no. 1-2, pp. 45–64, 1997.
- [150] K. Strömmand, E. Philipson, and M. A. Grönlund, “Offspring of male and female parents with thalidomide embryopathy: birth defects and functional anomalies,” *Teratology*, vol. 66, no. 3, pp. 115–121, 2002.
- [151] W. G. McBride and A. P. Read, “Thalidomide may be a mutagen,” *British Medical Journal*, vol. 308, no. 6944, pp. 1635–1636, 1994.
- [152] A. Broyl, R. Kuiper, M. van Duin et al., “High cereblon expression is associated with better survival in patients with newly diagnosed multiple myeloma treated with thalidomide maintenance,” *Blood*, vol. 121, pp. 624–627, 2012.
- [153] A. Lopez-Girona, D. Mendy, T. Ito et al., “Cereblon is a direct protein target for immunomodulatory and antiproliferative activities of lenalidomide and pomalidomide,” *Leukemia*, vol. 26, pp. 2326–2335, 2012.
- [154] Y. X. Zhu, E. Braggio, C.-X. Shi et al., “Cereblon expression is required for the antimyeloma activity of lenalidomide and pomalidomide,” *Blood*, vol. 118, no. 18, pp. 4771–4779, 2011.
- [155] K. M. Lee, S. J. Yang, Y. D. Kim et al., “Disruption of the cereblon gene enhances hepatic AMPK activity and prevents high-fat diet-Induced obesity and insulin resistance in mice,” *Diabetes*, vol. 62, pp. 1855–1864, 2013.
- [156] T. Ito, H. Ando, and H. Handa, “Teratogenic effects of thalidomide: molecular mechanisms,” *Cellular and Molecular Life Sciences*, vol. 68, no. 9, pp. 1569–1579, 2011.
- [157] K. Dredge, R. Horsfall, S. P. Robinson et al., “Orally administered lenalidomide (CC-5013) is anti-angiogenic in vivo and inhibits endothelial cell migration and Akt phosphorylation in vitro,” *Microvascular Research*, vol. 69, no. 1-2, pp. 56–63, 2005.
- [158] L. Lu, F. Payvandi, L. Wu et al., “The anti-cancer drug lenalidomide inhibits angiogenesis and metastasis via multiple inhibitory effects on endothelial cell function in normoxic and hypoxic conditions,” *Microvascular Research*, vol. 77, no. 2, pp. 78–86, 2009.
- [159] M. Ema, R. Ise, H. Kato et al., “Fetal malformations and early embryonic gene expression response in cynomolgus monkeys maternally exposed to thalidomide,” *Reproductive Toxicology*, vol. 29, no. 1, pp. 49–56, 2010.
- [160] F. S. Vianna, L. Fraga, L. Tovo-Rodrigues et al., “Polymorphisms in the nitric oxide synthase gene in thalidomide embryopathy,” *Nitric Oxide*, vol. 30, pp. 89–92, 2013.
- [161] K. Meganathan, S. Jagtap, V. Wagh et al., “Identification of thalidomide-specific transcriptomics and proteomics signatures during differentiation of human embryonic stem cells,” *PLoS One*, vol. 7, no. 8, Article ID e44228, 2012.
- [162] M. Brooun, A. Manoukian, H. Shimizu, H. R. Bode, and H. McNeill, “Organizer formation in Hydra is disrupted by thalidomide treatment,” *Developmental Biology*, vol. 378, pp. 51–63, 2013.
- [163] B. E. Hagstrom and S. Lonning, “The teratogenic action of thalidomide on marine fish larvae,” *Experientia*, vol. 33, no. 9, pp. 1227–1228, 1977.
- [164] M. Marin-Padilla, “Thalidomide injury to an implanted armadillo blastocyst,” *The Anatomical Record*, vol. 149, pp. 359–361, 1964.
- [165] H.-J. Merker, W. Heger, K. Sames, H. Sturje, and D. Neubert, “Embryotoxic effects of thalidomide-derivatives in the non-human primate callithrix jacchus. I. Effects of 3-(1,3-dihydro-1-oxo-2H-isoindol-2-yl)-2,6-dioxopiperidine (EM 12) on skeletal development,” *Archives of Toxicology*, vol. 61, no. 3, pp. 165–179, 1988.
- [166] C. J. J. Lee, L. L. Goncalves, and P. G. Wells, “Resistance of CD-1 and ogg1 DNA repair-deficient mice to thalidomide and hydrolysis product embryopathies in embryo culture,” *Toxicological Sciences*, vol. 122, no. 1, pp. 146–156, 2011.
- [167] J. A. Dipaolo, H. Gatzek, and J. Pickren, “Malformations induced in the mouse by thalidomide,” *The Anatomical Record*, vol. 149, pp. 149–155, 1964.
- [168] S. Fabro and R. L. Smith, “The teratogenic activity of thalidomide in the rabbit,” *The Journal of Pathology and Bacteriology*, vol. 91, no. 2, pp. 511–519, 1966.
- [169] S. Fabro, R. L. Smith, and R. T. Williams, “Toxicity and teratogenicity of optical isomers of thalidomide,” *Nature*, vol. 215, no. 98, p. 296, 1967.
- [170] I. D. Fratta, E. B. Sigg, and K. Maiorana, “Teratogenic effects of thalidomide in rabbits, rats, hamsters, and mice,” *Toxicology and Applied Pharmacology*, vol. 7, no. 2, pp. 268–286, 1965.
- [171] L. M. Newman, E. M. Johnson, and R. E. Staples, “Assessment of the effectiveness of animal developmental toxicity testing for human safety,” *Reproductive Toxicology*, vol. 7, no. 4, pp. 359–390, 1993.
- [172] M. Parkhie and M. Webb, “Embryotoxicity and teratogenicity of thalidomide in rats,” *Teratology*, vol. 27, no. 3, pp. 327–332, 1983.
- [173] K. T. Szabo and R. L. Steelman, “Effects of thalidomide treatment of inbred female mice on pregnancy, fetal development, and mortality of offspring,” *American Journal of Veterinary Research*, vol. 28, no. 127, pp. 1829–1835, 1967.
- [174] K. T. Szabo and R. L. Steelman, “Effects of maternal thalidomide treatment on pregnancy, fetal development, and mortality of the offspring in random-bred mice,” *American Journal of Veterinary Research*, vol. 28, no. 127, pp. 1823–1828, 1967.
- [175] C. J. J. Lee, L. L. Gonçalves, and P. G. Wells, “Embryopathic effects of thalidomide and its hydrolysis products in rabbit embryo culture: evidence for a prostaglandin H synthase (PHS)-dependent, reactive oxygen species (ROS)-mediated mechanism,” *The FASEB Journal*, vol. 25, no. 7, pp. 2468–2483, 2011.
- [176] K. T. Al-Jamal, W. T. Al-Jamal, S. Akerman et al., “Systemic antiangiogenic activity of cationic poly-L-lysine dendrimer delays tumor growth,” *Proceedings of the National Academy of Sciences of the United States of America*, vol. 107, no. 9, pp. 3966–3971, 2010.
- [177] A. Jurand, “Early changes in limb buds of chick embryos after thalidomide treatment,” *Journal of Embryology and Experimental Morphology*, vol. 16, no. 2, pp. 289–300, 1966.

- [178] M. S. Christian, O. L. Laskin, V. Sharper, A. Hoberman, D. I. Stirling, and L. Latriano, "Evaluation of the developmental toxicity of lenalidomide in rabbits," *Birth Defects Research B*, vol. 80, no. 3, pp. 188–207, 2007.
- [179] F. Chung, J. Lu, B. D. Palmer et al., "Thalidomide pharmacokinetics and metabolite formation in mice, rabbits, and multiple myeloma patients," *Clinical Cancer Research*, vol. 10, no. 17, pp. 5949–5956, 2004.
- [180] J. Lu, N. Helsby, B. D. Palmer et al., "Metabolism of thalidomide in liver microsomes of mice, rabbits, and humans," *Journal of Pharmacology and Experimental Therapeutics*, vol. 310, no. 2, pp. 571–577, 2004.
- [181] D. Veselá, D. Veselý, and R. Jelínek, "Embryotoxicity in chick embryo of thalidomide hydrolysis products following metabolic activation by rat liver homogenate," *Functional and Developmental Morphology*, vol. 4, no. 4, pp. 313–316, 1994.
- [182] J. Knobloch, K. Reimann, L.-O. Klotz, and U. Rüther, "Thalidomide resistance is based on the capacity of the glutathione-dependent antioxidant defense," *Molecular Pharmaceutics*, vol. 5, no. 6, pp. 1138–1144, 2008.
- [183] R. J. D'Amato, S. Lentzsch, K. C. Anderson, and M. S. Rogers, "Mechanism of action of thalidomide and 3-aminothalidomide in multiple myeloma," *Seminars in Oncology*, vol. 28, no. 6, pp. 597–601, 2001.
- [184] S. Lentzsch, M. S. Rogers, R. LeBlanc et al., "S-3-amino-phthalimido-glutarimide inhibits angiogenesis and growth of B-cell neoplasias in mice," *Cancer Research*, vol. 62, no. 8, pp. 2300–2305, 2002.



Hindawi

Submit your manuscripts at
<http://www.hindawi.com>

